Karolinska Institutet Danderyd Hospital
Department of Orthopaedics
Karolinska Institutet

A Clinical Study of Uncemented Hip Arthroplasty

Radiological findings of host-bone reaction to the stem

Henrik Bodén

2006

A Clinical Study of Uncemented Hip Arthroplasty
Radiological findings of host-bone reaction to the stem
By: Henrik Bodén
Layout: Anneli Holmsten, DataMedic AB, Stockholm
Cover illustration: Andreas and Richard Bodén

ISBN: 91-7140-677-8
2006

In the Footsteps of our Forefathers
for the Victories of Tomorrow

I Fäders Spår för Framtids Segrar

Contents

List of Original Papers

Paper I
Unstable versus stable uncemented femoral stems. A radiological study of periprosthetic bone changes in two types of uncemented stems with different concepts of fixation.
Bodén H, Adolphson P, Öberg M.
Arch Orthop Trauma Surg 2004; 124 (6): 382-92.

Paper II
No adverse effects of early weight bearing after uncemented total hip arthroplasty. A randomized study of 20 patients.
Bodén H, Adolphson P.
Acta Orthop Scand 2004; 75 (1): 21-9.

Paper III
Periprosthetic proximal bone loss after uncemented hip arthroplasty is related to stem size. A study of the Bi-Metric stem using dual-energy X-ray absorptiometry in 138 patients.
Sköldenberg O, Bodén H, Salemyr M, Ahl T, Adolphson P.
Acta Orthop 2006. In press.

Paper IV
Total hip arthroplasty with an uncemented hydroxyapatite coated tapered titanium stem. Excellent results at a minimum of 10 years follow-up in 104 hips.
Bodén H, Salemyr M, Sköldenberg O, Ahl T, Adolphson P.
J Orthop Sci 2006. In press.

Paper V
Continuous periprosthetic bone loss after operation with a tapered uncemented stem. A long-term evaluation with DEXA.
Bodén H, Sköldenberg O, Salemyr M, Lundberg H-J, Adolphson P.
Submitted to Acta Orthop 2006.

Abbreviations and Definitions

BMD:	Bone Mineral Density
CoCr:	Cobalt-chrome
DEXA:	Dual-Energy X-ray Absorptiometry
HA:	Hydroxyapatite
HHS:	Harris Hip Score
PMMA:	Polymethylmethacrylate
PTFE	Polytetrafluoroethylene
RSA:	Radiostereometric Analysis
THA:	Total Hip Arthroplasty
Ti-6Al-4V:	Titanium-6Aluminium-4Vanadium

Bone ingrowth:	Many terms are used interchangeably to describe the biological response when new bone tissue is found in direct contact with a surface of non-cemented implants; bone ongrowth, osseointegration, biological ingrowth etc. Initially, bone ingrowth was denoted ingrowth to porous surfaces but now it is most often applied equally to any type of implant. The level of resolution of the direct contact is not clearly defined.
Bone remodelling:	In this thesis, the term bone remodelling refers to mechanically adaptive changes in bone architecture.
Osseointegration:	A direct structural and functional connection between ordered, living bone and the surface of a load-carrying implant.
Pedestal sign/formation:	Radiological endosteal densifications at the tip of the stem, partiallly or completely bridging the medullary canal. *Synonym:* Tip sclerosis.
Porous coating:	Coating on an implant deliberately applied to contain void regions with the intent of enhancing the fixation of the implant.
Reactive lines:	Radiological endosteal densifications parallel to the lining of the implant, normally within millimeters distance from the implant surface. *Synonyms:* Radiopaque lines, radiodense lines, cortical lines, sclerotic lines.
Radiolucent lines:	Linear radiolucencies lining the implant contour without densifications. By some authors used interchangeably with reactive lines.
Spot weld:	Endosteal new bone formation bridging from the cortical bone and in apposition to the implant surface, seen as densification on radiographs.

Abstract

In total hip arthroplasty (THA), the main reason for failure leading to revision is aseptic loosening. Both mechanical and biological effects act in the loosening process, the factors may be implant design, fixation mode or technique, as well as biological factors unique to the individual. Younger and more active patients have a worse outcome compared to older patients. In an attempt to reduce the incidence of aseptic loosening, uncemented implants were introduced.

The load that is transferred over the artificial joint is taken up by the femoral implant and a significant fraction of the load is transferred further distally to the host bone. An adaptive bone remodelling occurs and is commonly discussed in terms of stress-shielding. The general aim of the study was to evaluate the outcome after operation with an uncemented femoral stem and how the femoral host bone reacts in terms of adaptive remodelling.

Material and Methods

Two types of tapered uncemented stems were evaluated. One stem with the surface coated with polytetrafluoroethylene, designed to enhance fibrous tissue ingrowth (Anaform®). One titanium stem with a proximal porous and hydroxyapatite coating, designed for bone ingrowth (Bi-Metric®). Clinical outcome was evaluated with the Harris Hip Score. Changes in bone mineral density (BMD) were assessed by Dual-energy X-ray Absorptiometry (DEXA). Bone metabolism was assessed by scintigraphy and radiological changes were noted using the criteria of Engh et al.

Study I

The two types of stems were compared eight years postoperatively. The stem coated with polytetrafluoroethylene showed signs of instability and a more generalized distribution of bone resorption. The proximally coated stem showed most pronounced resorption proximally, despite only proximal coating.

Study II

In a randomized controlled study, immediate and late weight-bearing after uncemented THA, were evaluated. Immediate weight-bearing had a positive effect on BMD around the prosthesis. No adverse clinical or radiological sign were detected.

Study III

In 138 patients with unilateral uncemented stems, BMD was evaluated after a mean of 41 months. The size of uncemented stems was found to correlate with periprosthetic BMD. Bone loss in the proximal periprosthetic regions was significantly associated with larger stem sizes.

Study IV

104 hips in 95 patients were followed for a minimum of 10 years after uncemented THA with the Bi-Metric® stem. Excellent radiological results were noted for the stem. No stem was revised and no sign of loosening was detected, despite an inferior result on the acetabular side with 23 failures. However, progressive remodelling was noted on the femoral side, also between five and ten years.

Study V

Two groups of 14 patients were followed for 10 and 14 years with DEXA and radiographs after implantation of the Bi-Metric® stem. At follow-up, a continuing decrease in BMD up to 14 years was noted in the calcar region.

In conclusion, fibrous fixation of an uncemented stem is insufficient. A tapered titanium stem, porous and hydroxyapatite coated in the proximal region, showed signs of bone ingrowth and excellent clinical result after 10-14 years. Radiological signs of stress-shielding and proximal periprosthetic bone resorption are continuous up to 14 years.

Key words: Arthroplasty, bone remodelling, DEXA, fixation, geometrical design, hydroxyapatite, osteoarthritis, scintigraphy, stem size, stress-shielding, tapered, titanium, uncemented, weight-bearing.

Background

Introduction

Total hip arthroplasty (THA) is one of the most successful surgical procedures that has been introduced and today over 1.5 million THA's are performed annually in the world. The development of THA in the 60's by Sir John Charnley represents a milestone in orthopaedic surgery. The most common indication for THA is primary osteoarthritis, a degenerative disorder of the cartilage and the surrounding tissues. This and several others disabling disorders of the hip joint can most often be successfully treated by THA. However, 8-9% of the THA's performed in Sweden, sooner or later need to be re-operated[78]. Revision arthroplasty is a challenging procedure, costly and with a less reliable outcome. The main reason for failure leading to revision is aseptic loosening. Both mechanical and biological effects act in the loosening process, the dominating factor may be one or the other, depending on a number of circumstances, including implant design, fixation mode and technique, as well as biologic factors unique to the individual. In the past decades, a number of innovations and technological refinements have been introduced. Many of these have resulted in a significant reduction in revision rates while other innovations have failed to live up to their promises. Practices and techniques of the past were, in some instances, superior to those more recently used. These facts bring about the importance of learning from history before taking the next step into the future.

Before 1950, the most common cause for hip surgery was devastating joint infections, mainly tuberculosis and acute bacterial joint infections, which befell mainly children and young adolescent people. The osteoarthritis, the worn out joint disease, on the other hand, was, before the era of the antibiotics rather a minor affection, remarkably well tolerated by older people. After 1950 primary and secondary osteoarthritis has been the prevailing joint ailment leading to hip surgery followed by rheumatoid arthritis and remnants after childhood hip diseases. Besides antibiotics, the change is explained by the increased number of aged people with a higher demand for an active daily life. However, the main reason is probably the improved clinical results caused by the development work over the years, in terms of material and surgical techniques.

Early History

Until the 19th century, limb amputation or possibly joint resection was the techniques of choice for a diseased joint. Professor Themistocles Gluck[66] (1853-1942) designed the first endoprosthesis when he in the 1880's implanted artificial total joints fabricated from ivory. It is said that Gluck exerted himself to the utmost to change the contemporary surgery ”from being the destructive art to become the reconstructive art”.

Since almost all joints, which were reconstructed, were infected, Gluck and his successor Jules Emile Péan[141] (1830-1898), who used rubber and platinum, were not successful enough. It was not until Marius Nygaard Smith-Petersen[133] in Boston, in 1923 started to reshape and cover femoral heads with his ”mold arthroplasty” that good results were obtained, especially after the adoption of cups made of vitallium (cobalt-chrome alloy), the first nonreactive metal alloy to be used in orthopaedic surgery. Even though cases of extremely long time survival is reported[149], the technique could not routinely be expected to succeed.

In 1938 Philip Wiles[186] in London first introduced the idea of a THA consisting of a femoral component secured to the neck of the femur by a bolt and an acetabular component anchored to a buttress plate by screws. The prosthesis was made of stainless steel. When Wiles first reported the results of his procedure, he stated that they were not at all satisfactory due to loosening and breakage.

The brothers Robert and Jean Judet[91], in 1946 in Paris, returned to the concept of replacing the femoral head. They introduced polymethylmethacrylate (PMMA), formed as a knob, to replace the femoral head and a plastic stem passing down the neck. A stunningly successful immediate result was followed by disappointment after a few years. The mechanical properties of PMMA did not withstand the stresses at the hip. However, the concept of an intramedullary stem was accepted and another concept of hemiarthroplasty, with a long-stemmed metal implant made of vitallium, was reported by Austin Moore[129] in 1942 and a similar device was later introduced by Frederick Thompson[174], both from USA. The stem was placed into the marrow cavity of the femur, connected in one piece with a metal ball which was fitted into the acetabulum. Giving improved durability, the prostheses were initially employed for arthrosis. However, the less congruent head eroded the native acetabulum, in addition, there was no effective method to secure the femoral component to the bone. The main indication became femoral neck fractures in less demanding patients.

When hemiarthtroplasty became popular in treatment of femoral neck fractures, it was logical to expand the operation to include an acetabular component. Many metal combinations were introduced; by McKee and Watson-Farrar[123] and Ring[155] in England, and by several others in the USA. The results of these first THAs were not entirely satisfactory because of problems with loosening and wear between the opposing metal surfaces.

Haboush[71] in New York, adopted the use of a fast-setting self-curing dental acrylic cement for fixation of his vitallium total hip prosthesis, a new era of fixation seemed to have been opened. However, the problems to replace a hip joint remained unsolved until John Charnley[30] in England presented his concept of ”low friction arthroplasty”. He had also adopted the cementing technique (methylmethacrylate) and aggressively pursued effective methods of replacing both the femoral head and the acetabulum of the hip. When the first series of polytetrafluoroethylene (PTFE, Teflon®) cups, which suffered from excessive wear, was changed to the much more resistant polyethylene, good long-term results were obtained when combined with a head of a small diameter (22 mm) for improved frictional torque. Wrightington, Manchester, became during the 60’s a well-spring of knowledge for the surgical treatment of arthritis. The long-term results became very predictable[31] and Her Majesty the Queen of England knighted him for his immense contributions.

Since Charnley’s days, there has been considerable efforts and research to improve the method of fixation. The technique of cemented fixation is still the prevailing concept in most countries and it has been refined with significant improvement as shown in the Swedish National Hip Register[79]. However, it is generally agreed that the cemented interface has limitations in the capacity to endure the forces that occur in the human hip. In the younger and more active population, with higher functional demands and a long expected lifetime, the results have been less favourable and several attempts with various concepts have been made to overcome the stress, strain and time dependent cement fixation.

Uncemented Implants, Substrates and Surfaces

If a living type of bond could be created, with a capability to accommodate to the physiological stress distribution, a dynamic remodelling would be obtained. Theoretically, a longer lasting and possibly stronger interface would be achieved. In the late 1960’s and early 1970’s the first reports of biological fixation with porous metals came. Both cobalt-chrome alloys and commercially pure titanium were shown to allow bone ingrowth if the surface was porous[144] or textured with sintered fiber metal[59]. Later on, it was proven that titanium alloy, which was less roughened by blasting, also provides an excellent surface for implant integration to the bone[165,180]. Other surface coating materials such as porous polyethylene[132], porous polysulfone[164] and Teflon[175] were studied. They did not cause bone ingrowth but a fibrous fixation which, if constituted of well organized collagen fibers, may function as an anchorage for implants[145,182,184]. It may also serve as a shock absorber, reduce peak stresses, uniform stress transfer from prosthesis to bone and thereby permitting micromotion without inducing harmful effects to the bone. However, biomechanical tests have shown lower removal forces for fibrous fixated implants[167] and their clinical results are unpredictable[132,175], why polymers have been discontinued as a surface material in hip implants.

The term *bone ingrowth* refers to actual new bone formation within the porous surface structure of any porous implant. The term *osseointegration* is originally referred to the intimate contact of bone to the surface of commercially pure titanium described by Brånemark[17] and Albrektsson[2] in Gothenburg, Sweden. On the surface of a commercially pure titanium implant there are instantly formed several oxide layers. Titanium dioxide (TiO_2) is the most stable and most common oxide under physiological conditions. The oxidized surface is hard and very resistant to corrosion. It is the only surface that the host tissue comes in contact with; therefore, the titanium oxide is of an utmost importance for the host bone reaction. The strength of the bond between bone and titanium implants is of the same magnitude as bone itself, also in tension. It indicates a strong chemical or microinterlock bond which is also proposed by an apposition of calcification to the titanium oxide layer as close as the resolution level of the electron microscope[75]. However, the term osseointegration is often referred to as a well integrated implant even though a histologic evaluation was not carried out. Since titanium shows a high degree of biocompatibility, resistance to corrosion and also resembles the host bone elasticity more than other metals, it has been widely adopted as an implant material. If the surface is roughened, a significantly stronger integration is achieved as shown by Carlsson et al.[28]. However, the strength of pure titanium is somewhat less than cobalt-chrome, an alloy widely used in uncemented porous surfaced implants since the early 80's[45]. If titanium is alloyed with 6% aluminium and 4% vanadium (Ti-6Al-4V) it was found to have superior mechanical properties compared to pure titanium but still had a low modulus of elasticity. When titanium alloy implants were first introduced as a monobloc stem implants, the tribological properties were not fully understood[57]. Poor wear behaviour and tissue metallosis were observed besides a less than optimal fixation if cementing technique was used. Stems with modular heads, manufactured from more wear resistant materials, were introduced and titanium alloy stems are today, almost exclusively, used for biological fixation without cement.

To enhance the osteoconductive properties, Ti-6Al-4V is often coated with a thin layer of titanium roughened to a porous surface by either beaded microspheres, fiber-metal or plasma-spray to encourage microinterlock and to provide a larger area for ongrowth. Wear debris from the articulating surfaces is often proposed as an important factor in the process of loosening by inducing an inflammatory tissue reaction and local bone resorption[86,156]. To prevent migration of wear debris and inflammatory agents along the metal stem-bone interface and thereby inhibit loosening, a circumferential proximal coating is now advocated[40,176].

Early in the history of uncemented implants it was revealed that, despite a porous and biocompatible substrate, a thin layer of fibrous membrane frequently separated the prosthesis from the bone, partly or around the implant. The local environment, in particular initial instability, was shown to be an important factor in this respect. In an attempt to achieve early stability and reproducible bone ingrowth to the implant, trials on bioactive calcium phosphate ceramic coatings were carried out. Chemically, the constitution of hydroxyapatite (HA) $Ca_{10}(PO_4)_6(OH)_2$, tricalcium phosphate and fluoroapatite is close to that found in bone and has been investigated extensively. HA was adopted from dental reconstructive surgery and from the mid 80's it was first introduced to enhance the osteoconductive properties of uncemented hip implants[55,62,136]. It was confirmed how supplementary HA had the ability to enable bone to bridge over wider gaps and to do that more rapidly. Within the gap, bone formation was induced not only from the side of the host bone but also from the side of the HA implant. It was also proven that HA coated implants allowed a better fixation to the bone despite a less stable situation compared to non HA coated implants[170].

There have been concerns about slow resorption of the calcium phosphate coating and particle release from wear and abrasion[12]. Research has shown that the quality of the HA, regarding the degree of crystallinity, porosity, application method and coating thickness, are all key parameters for mechanical and fixation properties[137]. HA-coating on a porous surface has shown a stronger mechanical fixation in canine models but highly crystalline hydroxyapatite applied on blasted surfaces has also been reported to perform excellent for 10-15 years clinically[26,160]. With HA coated implants, a decreased micromotion soon after implantation has been identified by radiostereometric analysis (RSA) in comparative studies with non-HA coated implants[108,153]. Over the years, HA is gradually replaced by bone and even if postitive effects have been reported radiographically[38], and histologically[34], after several years in situ, many surgeons question the necessity of this expensive coating.

Geometrical Designs

One of the first disadvantages, experienced from the first generation of uncemented stemmed femoral prostheses, was the varying stability inside the femoral cavity. Besides a less than optimal metal substrate, surface properties and surgical technique, the poor fixation can be assigned to a less than optimal geometrical design. However, still today divergent opinions are prevalent regarding the geometry of an uncemented stem. It is generally agreed on that instant mechanical stability is a prerequisite for bone ingrowth and long-term fixation. By which principles these goals best can be achieved, are most conveniently explained by the four main concepts of geometrical designs on the market.

The *straight cylindrical* stem was among the first designs that showed good results and is still widely used in USA. Primary stability is achieved by reaming the diaphyseal femur and, with a tight fit, a long, non-tapered, cylindrical stem is inserted down through the femoral shaft. Excellent primary stability is achieved and bone ingrowth is obtained on a porous surface along the femoral shaft where much of the load is transferred to.

The *anatomic* stem is designed to achieve maximum fixation in the metaphyseal region to concentrate as much off-loading of the stem in this region as possible. Precise proximal fit is emphasized for this reason. This implant is anatomically shaped, usually slightly curved and manufactured with a left and right side version.

The *tapered* stem was also designed with the aim for proximal fit and fixation. This is provided by wedging the stem into a tight mechanical fit which is normally achieved in the lower metaphyseal or isthmus region. Less attention is paid to the host bone anatomy and the more distal femur. A collar may hinder firm seating of the implant.

The *press-fit* stem relies on the initial mechanical joining of the implant to the bone by high contact pressure. This is obtained by the elastic recoil of the bone and of the slightly oversized implant towards each other. The surgeon does not aim for an exact fit by extensive preparation of the femoral cavity but is rather saving endosteal tissue for physiological reasons.

There are also several uncemented stems on the market, whose geometrical design less obviously can be categorized into these four main concepts.

An increasing number of reports confirms excellent clinical result from series with modern uncemented stems from all four concepts of geometrical designs, also in the mid- to long-term perspective[3,94,116,135]. For the first time, it was recently shown on a nationwide level from Finland, that in younger individuals, modern uncemented stems performed best in terms of implant survival rate at ten years[53].

With modern uncemented implants and good surgical technique, primary stability and bone ingrowth are no longer the main issues. However, a phenomenon called *stress-shielding* was early noted and can, to a varying degree, be seen with all types of prosthetic stems.

Stress-shielding

The load that is transferred over the artificial joint is taken up by the femoral implant and a significant fraction of the load is transferred further distally to the host bone. Adaptive bone remodelling occurs and reflects the altered mechanical environment caused by the implant. The reduction in mechanical loading of the periprosthetic bone proximally, and the adaptive atrophy that follows, are commonly discussed in terms of stress-shielding. It is of vital importance to clearly distinguish this *adaptive resorption* from the *pathologic resorption* seen as a tissue response, mainly to the presence of particle wear debris, which is known as osteolysis. Osteolysis is considered to be an inflammatory reaction with an entirely different etiology and radiological appearance. Typically, osteolysis is seen as one or more localized cystic lesions with well-defined borders or as radiolucent lines along the interface of the implant. The mechanically induced adaptive bone resorption due to stress-shielding as a mechanism for prosthetic failure is controversial[64,120] and it is one of the main subjects for this thesis. A severe case of stress-shielding is shown in Figure 1.

Although the occurrence of periprosthetic bone loss after THA has been recognized since many years, it has been difficult to quantify and study in detail. On plain radiographs, bone loss is not significantly detected until about 30% of the bone is lost and the loss is not reproducibly recognized until 70% of the bone is resorbed[50]. With the introduction of dual-energy x-ray absorptiometry (DEXA) in the early 90's, it became possible to noninvasively measure bone mineral content (BMC) in vivo, also adjacent to a metallic implant. If the BMC is divided by the projected area of the region of interest, the areal bone mineral density (BMD) is achieved. BMD, expressed as g/cm^2, is the most commonly used measurement when quantification of bone changes is reported.

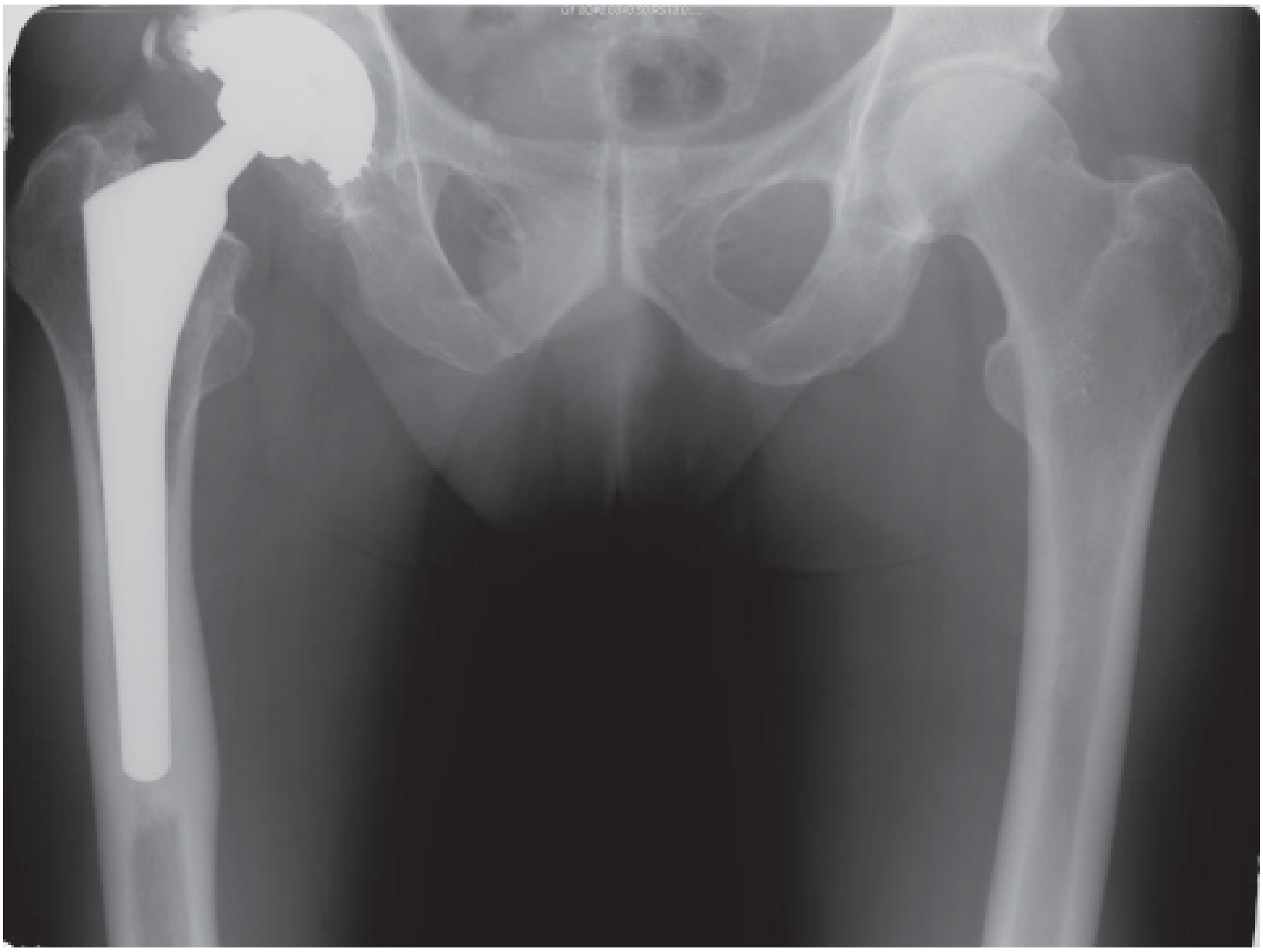

Figure 1. An example of obvious stress-shielding.

Aims of the Study

The general aim of the study was to evaluate the outcome after operation with an uncemented femoral stem used in THA and how the femoral host bone reacts in terms of adaptive bone remodelling. Our specific aims of these investigations were:

I To evaluate how the factors *fixation mode* and *stability* influence the clinical outcome, remodelling and periprosthetic bone metabolism in the mid-term perspective.

II To evaluate how the factor *postoperative loading* influences the clinical outcome, remodelling and periprosthetic bone metabolism in the short-term perspective.

III To evaluate how the factor *stem size* influences the clinical outcome and periprosthetic bone remodelling in the short- to mid-term perspective.

IV To evaluate the clinical and radiological results, at minimum 10 years, after implantation of an uncemented stem.

V To evaluate the factor *time in situ* on the longitudinal changes in periprosthetic bone remodelling.

Patients, Materials and Methods

Patients

THA without cemented fixation has been performed at the orthopaedic department, Danderyds Hospital, Stockhom since 1985. Between 1985 and 1989, patients were operated on with the uncemented Anaform® femoral prosthesis combined with the uncemented Ceraver acetabular screw-in cup. In 1989, the implants were changed to the uncemented Bi-Metric® femoral prosthesis combined with the uncemented Romanus acetabular screw-in cup or a cemented all polyethylene cup. The selection criteria for uncemented THA included age under 70 years, a good general health, good bone quality with no cortical thinning or defects and no severe abnormality of the proximal medullary canal. All patients were operated on by a senior surgeon through a standardized posterior approach without removal of the greater trochanter or section of the abductor muscles of the hip. All patients were mobilized, on the day after the operation, under the supervision of a physiotherapist.

All together 275 hips in 267 individuals were completely evaluated according to the protocols in the five studies. Ten of the patients from **I** were also included in **IV** and **V**. Fourteen patients in **III** were also included in **V**.

In **I-III** and **V**, strict exclusion criteria were used to avoid patients with earlier hormonal therapy, other medication or illness known to affect the bone metabolism. Only patients without earlier fractures or other disabilities of the contralateral leg, which might interfere with proper assessment, were included. In **IV**, regardless of surgical cause, all consecutive patients who fulfilled the indications, in accordance with the routines of the department, were included. The patients gave their informed consent before inclusion into the studies. The investigations were approved by the ethic's committee of the Karolinska Hospital.

Materials

Ten patients in **I** were operated on with an uncemented femoral prosthesis (Anaform®) with a modular head of cobalt-chrome and a fixed neck length and a head diameter of 32 mm (Vitek Inc., Houston, Texas, USA). The stem prosthesis (cobalt-chrome-molybden alloy) was available in

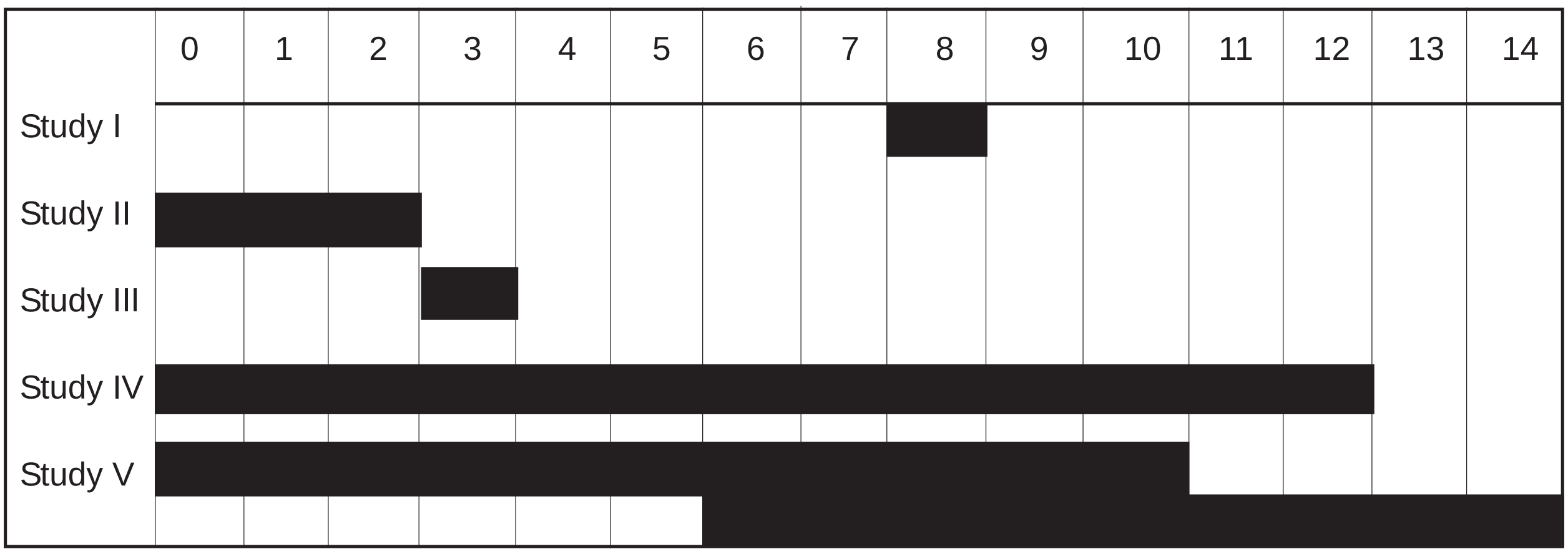

Figure 2. Follow-up time (years).

six proportional sizes and was coated with a composite of polytetrafluoroethylene reinforced with carbon fiber (Proplast®, Vitek Inc., Houston, Texas, USA). On the acetabular side, all these patients received an uncemented, non coated, threaded screw-in cup with a cylindrical polyethylene liner.

All other patients in the studies (**I-V**) received an uncemented femoral prosthesis, Bi-Metric®, (Biomet Inc., Warsaw, Indiana, USA). It has a collarless stem made of a titanium alloy (Ti-6Al-4V), where the proximal one-fourth has a circumferential, plasma-sprayed, titanium alloy porous-coating with a mean pore size of 300 µm. The distal part has a textured surface with a roughness of 6.9 µm. The porous part has a plasma-sprayed HA layer of 40-70 µm thickness, crystallinity of 50-70% and a purity of >95%. The stem has a straight 3° proximal to distal taper in two planes and a taper from the lateral shoulder to the medial calcar area which angle increases with the size of the implant. The stem articulates with a 28 mm modular cobalt-chrome head of varying neck extension lengths (-6, 0, +6 mm). The stem is available in proportional sizes from 7 to 19 mm with corresponding lengths of 115 to 175 mm. The Bi-Metric® stem was combined with an uncemented, titanium alloy, porous and HA coated, threaded, screw-in cup in 197 hips. In those, an ultra-high density polyethylene liner was inserted. Before 1995, when patients in **I**, **IV** and **V** were operated, the liner had a snap-fit locking mechanism (Hexloc®). From 1995, the design of the locking mechanism was changed to a ring locking mechanism. Because of the surgeons' preference, 68 Bi-Metric® stems were combined with an all-polyethylene cemented cup (64 in paper **III**, 4 in paper **IV**).

Methods

Clinical evaluation

The clinical condition was determined by use of the Harris Hip Score (HHS)[76], at all follow-up occasions (**I-V**). Points are apportioned as follows: pain (0 to 44); function, divided into activity, limp, distance walked, and support (0 to 47); physical examination, divided into deformity (0 to 4) and range of motion (0 to 5). See **I** for a detailed description.

In **III**, **IV** and **V**, we also graded thigh pain as: none, mild or pain limiting activity.

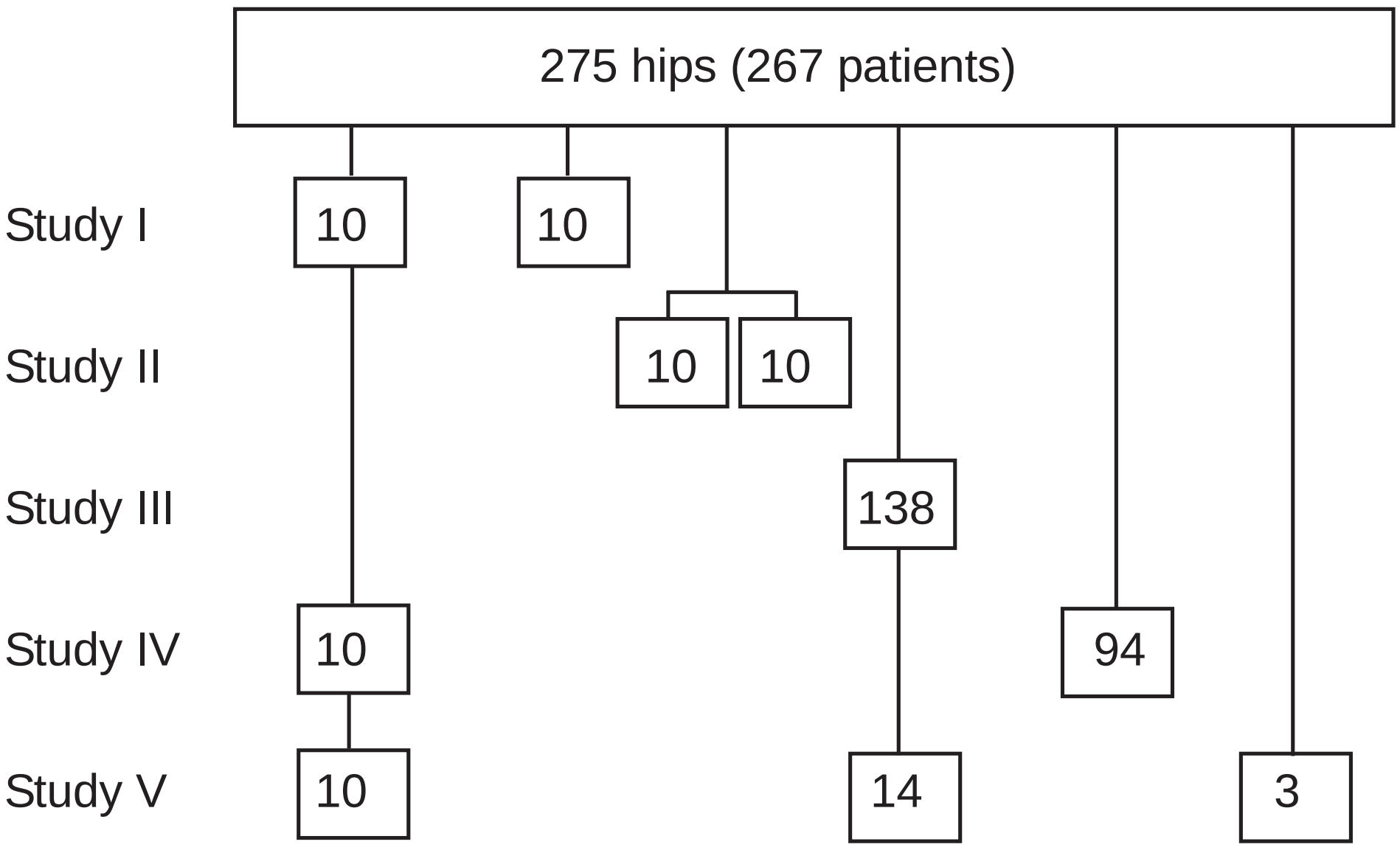

Figure 3. Distribution of evaluated hips.

In paper **II**, the patients were equipped with a battery-operated, pressure-activated auditory device incorporated in the sole of the shoe (pedisense™, Aggero Produkt & Affärsutveckling AB, Gothenburg, Sweden) to make sure of compliance regarding restricted weight-bearing. This auditory device warned the patients who were restricted from early weight-bearing by emitting a buzzer sound when the load on the extremity was too high. These patients were instructed to use the auditory sole always when walking and to record the frequency of sounds emitted during the early rehabilitation period, thus serving as a feedback for the patient during the first three months' period. The sole was equipped with two sensors in the forefoot and one sensor in the heel region. The load was calibrated using two loading devices, either with ”spots” which increased the sensitivity or ”rings” which decreased the sensitivity of the sole. The patients who were instructed to immediate weight-bearing used the device during physiotherapy as an indication for adequate loading of the operated leg.

DEXA

The BMD of the periprosthetic femur was measured in the coronal plane by a dual-energy x-ray absorptiometer, DEXA (DPX-L™, Lunar Co., Madison, Wisconsin, USA), (**I-III,V**). During scanning, the patient was placed supine with standard knee and foot supports and with the femur in neutral rotation. The scanner was equipped with a software for femoral periprosthetic bone mineral measurement[119]. This software detected the interface between the bony part and the prosthesis stem on the basis of density changes and simulated the stem in the form of a prosthesis mask which was superimposed on the healthy side. The healthy hip was scanned at the corresponding level and BMD in seven regions of interest (ROIs) based on Gruen's zones[70] were analyzed. The values were expressed as areal BMD, g/cm^2. The ratio between the operated side and the control side was calculated. The longitudinal changes on both sides were also recorded (**II, V**). To avoid the perioperative impact by surgery on periprosthetic BMD, we performed the first measurement within the first days after the operation as proposed by Kröger et al.[106] and Nishii et al.[131].

To estimate the precision error of the DEXA method, we have made double measurements in ten patients, with complete reposition of the patient and the scanner (Bodén et al., data on file). The precision error was 2.3% in BMD at Gruen zone 1, 1.0% in BMD at Gruen zone 2, 2.0% in BMD at Gruen zone 3, 3.5% in BMD at Gruen zone 4, 4.2% in BMD at Gruen zone 5, 1.3% in BMD at Gruen zone 6, and 3.7% in BMD at Gruen zone 7. This precision is of the same order as reported by Kilgus et al.[98] and Nishii et al.[131].

Scintigraphy

The scintigraphic activity in the periprosthetic femur was measured using a low-energy, general purpose collimator on a MAXXUS dual head gamma camera (GEMS, General Electric Co., Milwaukee, Wisconsin, USA), (**I, II**). The patients received an intravenous injection of 440 MBq of 99mTc-labeled methylene-diphosphonate. The imaging was performed after approximately four hours. No flow or blood pool images were acquired. With the patients in standardized position, anterior and posterior views of the upper femur were obtained. On the prosthetic side, three regions of interest (ROIs) were drawn corresponding to the periprosthetic bone in Gruen's zones 1, 4 and 7, respectively. The length of the prosthesis was taken into consideration. Thereafter, these three ROIs were mirror imaged and transferred to the unoperated upper femur. The same procedure was performed for the anterior and the posterior views. The counts per pixel were obtained in each of the 12 ROIs and the mean value from the anterior and the posterior views was calculated. To obtain an uptake ratio, the value of the operated side was divided by the corresponding value of the contralateral side for each zone. In paper **II**, also the longitudinal changes were recorded and expressed as an uptake ratio. The effective dose to the patient during the examination was approximately 3 mSv, which compares with the average dose received during a routine lumbar and pelvic radiography.

To estimate the precision error of the scintigraphy method, we have made double measurements in 10 patients by replacing the ROIs on both sides with usage of the same images. The precision error of the scintigraphic method was

3-6% in the Gruen's zones 1, 4 and 7 (Bodén et al., data on file).

Radiological evaluation

The radiological examination included three exposures; one pelvic view with the central beam projecting on the symphysis, one anterior-posterior view centered on the intertrochanteric region and one lateral view. The radiographs were assessed by the criteria of Engh's Fixation/Stability Score for uncemented femoral implants[46]. This instrument differentiates the assessed parameters into either signs predicting fixation by osseointegration or signs predicting implant stability without osseointegration, their relevance is determined by histological investigations and perioperative assessment at reoperations. Gross instability was defined as visible motion under stress of the bone-implant interface at reoperation. There are two Signs of Fixation: appearance/absence of spot welds and absence/appearance of reactive lines in the coated region of the stem. There are six Signs of Stability: absence/appearance of reactive lines in the non coated region, pedestal formation, calcar modelling, interface deterioration (widening radiolucent lines), migration and particle shedding. When there is evidence of fixation, the Signs of Stability always define stability. When Signs of Fixation are absent, the Signs of Stability grade the implant to a degree of stability provided by fibrous tissue.

Migration of the femoral implant was considered definite if there was a change in the vertical distance of 5 mm or more from the lateral shoulder to the most medial point of the lesser trochanter[114], (**I**). In **II-V**, where solely Bi-Metric® stems were evaluated, the distance between the easily identified inferior border of the coating to the most medial point of the lesser trochanter, was measured instead. Any change in alignment or rotation was recorded (**I-V**).

In addition to the parameters mentioned above, we also assessed presence of focal osteolysis (scalloping) with defined borders and distal cortical hypertrophy, defined as enlargement of the external femoral diameter around the distal part of the prosthesis compared to adjacent regions. We assessed the radiological changes according to the zones described by Gruen et al.[70] on the A-P radiographs (Figure 4).

Heterotopic ossification was recorded using the Brooker et al.[19] grading system, (**II, IV, V**). Linear wear was assessed by a digitized caliper by which the shortest distance from the femoral head to the outer border of the acetabular component was measured (**V**). This distance was subtracted from the outer radius of the cup subtracted with the radius of the head. Wear rate was obtained by dividing the wear distance by time in situ.

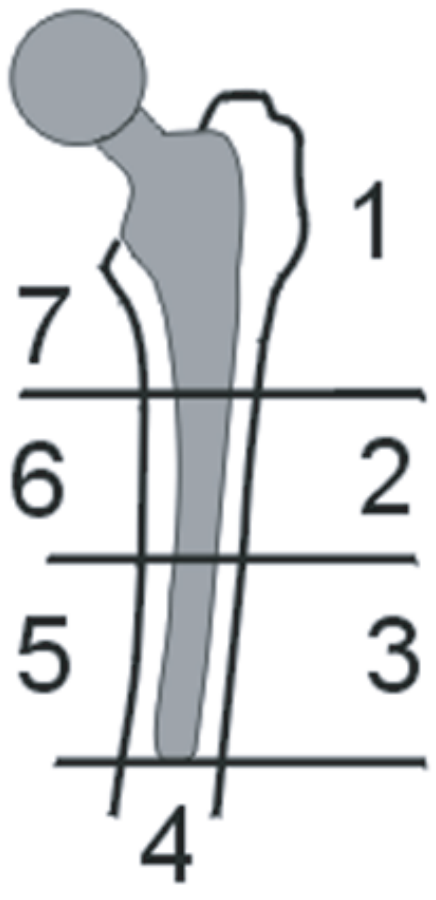

Figure 4. Gruen zones.

Summary of Papers

Paper I

Bodén H, Adolphson P, Öberg M. Unstable versus stable uncemented femoral stems. A radiological study of periprosthetic bone changes in two types of uncemented stems with different concepts of fixation. Arch Orthop Trauma Surg 2004; 124 (6): 382-92.

Objective: In recent years, uncemented concepts, with porous-coating or with ceramic coating such as hydroxyapatite, have shown promising results in the intermediate time span. However, aseptic loosening occurs here as well, and a worrying remodelling of the periprosthetic bone of the proximal femur has been noted. This study aimed to investigate how the host bone adapts to a loose uncemented stem compared to a well-fixed uncemented stem after a long time in situ. Evaluation of the clinical outcome, bone mineral changes, the scintigraphic pattern and the grade of remodelling of the proximal femur were performed.

Material and Methods: An investigation with the Harris Hip Score, dual-energy x-ray absorptiometry (DEXA), scintimetry and radiological assessment was carried out in 20 patients eight years after a THA operation with two different uncemented stems for arthritis. Ten patients received a stem coated with polytetrafluoroethylene (Anaform®) of which all prostheses were known to be only fibrous fixated. Ten patients received a tapered hydroxyapatite coated stem (Bi-Metric®) with bone ingrowth.

Results: Different remodelling patterns were seen. In the unstable group (Anaform®), the periprosthetic bone mineral density (BMD) was significantly reduced along the entire stem, while in the stable group (Bi-Metric®) only proximal bone loss was seen. The scintigraphic uptake was increased under the stem tip in both groups and among unstable stems uptake was still, after eight years, increased also in the calcar region under the collar. The signs of instability on plain radigraphs, described by Engh et al.[46] for fibrous fixated femoral implants, were in accordance with our results.

Paper II

Bodén H, Adolphson P. No adverse effects of early weight bearing after uncemented total hip arthroplasty. A randomized study of 20 patients. Acta Orthop Scand 2004; 75 (1): 21-9.

Objective: Initial stability is a prerequisite for bone ingrowth onto uncemented implants. Immediate weight-bearing after an uncemented THA could cause micromovements at the bone-implant interface, jeopardizing stability and ingrowth of the implant. The aim of this study was to investigate if immediate weight-bearing after implantation of a tapered, porous and HA coated uncemented femoral stem would affect the postoperative function, the ingrowth of the prosthesis or the remodelling pattern of the periprosthetic bone.

Material and Methods: Twenty patients younger than 65 years of age and with unilateral primary degenerative arthritis were randomly allocated to immediate or delayed weight-bearing (3 months). The patients were equipped with a battery-operated, pressure-activated auditory device incorporated in the sole of the shoe serving as a feedback. For the patients in the delayed weight-bearing group, the auditory device warned the patients by emitting a buzzer sound when the load was too high during the first three months' period. The patients in the immediate weight-bearing group were equipped with the auditory device during the hospital stay to encourage maximal weight-bearing. Clinical rating was determined by use of Harris Hip Score. Remodelling was assessed radiologically and BMD by DEXA after 0, 3, 6, 12 and 24 months. At 6, 12 and 24 months also technetium scintigraphy was performed.

Results: There was no difference in Harris Hip Score between the groups postoperatively.

We found a marked reduction in BMD on the operated femur in almost all Gruen zones in both groups already after three months, the largest reduction was noted proximally, where it was reduced by 21% in the group with delayed weight-bearing. There was a significant larger BMD loss in the group with delayed weight-bearing in Gruen zone 1, 4 and 5 after three months. Proximally, neither group recovered from the initial bone loss during the follow-up period. The scintigraphic uptake ratio was, in both groups, significantly increased on the operated side compared to the healthy side in all evaluated ROIs (Gruen zone 1, 4 and 7) after six months. After 24 months, the scintigraphic uptake ratio had diminished but it was still increased by about 20%. There was no difference in scintigraphic uptake between the groups in any zone at any time. Radiologically, all femoral components appeared well-fixed with evidence of bone ingrowth. Since no migration was larger than 2 mm, measured on plain radiographs, no definite subsidence was considered to have occurred. With the tapered stem geometry, sufficient initial stability can be achieved to allow immediate weight-bearing.

Paper III

Sköldenberg O, Bodén H, Salemyr M, Ahl T, Adolphson P. Periprosthetic proximal bone loss after uncemented hip arthroplasty is related to stem size. A study of the Bi-Metric stem using dual-energy X-ray absorptiometry in 138 patients. Acta Orthop 2006. In press.

Objective: A potential adverse proximal bone resorption has been associated with well-fixed uncemented stems. The relative stiffness of the implant, in comparison with the bone, is believed to be of major importance. This study was undertaken to investigate the degree of periprosthetic bone loss and its correlation to femoral stem size after implantation of a tapered titanium alloy stem proximally coated with porous titanium and HA.

Material and Methods: 138 patients with unilateral THA, performed with the uncemented Bi-Metric® stem, were evaluated with the Harris Hip Score, radiological assessment, and DEXA measurement after a mean of 41 (range, 24-80) months after surgery. The BMD ratio between the operated side and the healthy control side was compared to stem size.

Results: Harris Hip Score was mean 97 points. Radiologically, there was no sign of stem loosening. The BMD loss was most pronounced in the proximal zones. The correlation analysis indicated a relationship between stem size and bone loss in Gruen zone 1, 2, 6 and 7. Multiple regression analysis with stem size as the control variable showed no correlation between bone loss of the operated femur in any zone versus sex, age, weight, height, body mass index, implant time, initial BMD - expressed as BMD on the healthy femur - or Harris Hip Score.

Paper IV

Bodén H, Salemyr M, Sköldenberg O, Ahl T, Adolphson P. Total hip arthroplasty with an uncemented hydroxyapatite coated tapered titanium stem. Excellent results at a minimum of 10 years follow-up in 104 hips. J Orthop Sci 2006. In press.

Objective: Cemented arthroplasties have been shown to be durable over time on the femoral side and improved cementing technique has enabled the surgeon to consistently obtain a more adequate cement mantle. However, for the young and active individual, where the cemented concept has shown inferior results, the concept of biologic fixation with uncemented implant may prove to be a more reliable option. Since 1990, we have used an uncemented, tapered stem without collar (Bi-Metric®). We report our results after minimum 10 years of this prosthesis.

Materials and Methods: Between January 1990 and December 1993, a consecutive series of 115 primary THA in 105 patients with miscellaneous diagnoses were operated. Mean age at operation was 52 (range, 25-66) years. All patients received a stem made of a titanium alloy (Ti-6Al-4V), where the proximal one-fourth has a circumferential, plasma-sprayed porous-coating of titanium alloy and on top of that, a plasma-sprayed HA-coating. The stem was combined with an uncemented, porous- and HA coated, threaded, screw-in cup. A detailed clinical and radiological analysis was performed after minimum five and ten (mean, 12.2) years. Eight patients (ten hips) had died and one patient was lost to follow-up, leaving 104 hips for final evaluation. The clinical result was evaluated by Harris Hip Score, complications and thigh pain.

Results: All patients still had their femoral component in place at the final follow-up. Average HHS was 92, median 96 points. Two periprosthetic fractures have ocurred after trauma during the follow-up. Radiologically, several signs of progressive remodelling were identified but no stem showed sign of loosening.

Paper V

Bodén H, Sköldenberg O, Salemyr M, Lundberg H-J, Adolphson P. Continuous periprosthetic bone loss after operation with a tapered uncemented stem. A long-term evaluation with DEXA. Submitted to Acta Orthop 2006.

Objective: Uncemented femoral stems of modern designs have shown very promising results in the 10-years' time span with a good clinical outcome and persistent osseointegration. However, proximal femoral bone resorption, due to distal stress transfer, i.e., stress-shielding, seems to occur to a significant degree during the first year. The aim of this study was to determine the longitudinal changes in BMD around a tapered uncemented stem up to 15 years postoperatively.

Materials and Methods: A consecutive group of 14 patients with unilateral hip arthritis (group A) received an uncemented tapered titanium stem with proximal porous- and HA-coating. They were followed with HHS, radiographs and DEXA from one week postoperatively and thereafter at 6, 12, 24 and 120 months postoperatively. To prolong the observation time, another group of 13 consecutive patients with unilateral hip arthritis operated on 1990 to 1992 (group B) was evaluated at 74 months and 173 months (6.2 and 14.4 years, respectively) postoperatively with HHS, radiographs and DEXA.

Results: No stem has been revised and no stem showed radiological sign of loosening. HHS was mean 97 (group A) and 94 (group B) points. Obvious remodelling changes, due to distal load transfer, were recorded in the periprosthetic bone. With DEXA, a significant decrease in BMD was noted in the proximal zones during the first six months postoperatively. After this initial phase, a retardation of the BMD changes occurred. However, in the calcar region (Gruen zone 7), the decrease in BMD was significantly more rapid also between 2 and 10 years (group A) and between 6.2 and 14.4 years (group B), compared to the unoperated side. The largest difference in BMD was seen in zone 7 where there was a mean loss of 41% (range, 33-59) after 14.4 years.

Discussion

Discussion on Materials

Polytetrafluoroethylene

In study **I**, a stem coated with polytetrafluoroethylene (PTFE), reinforced with carbon fiber, was used. Charnley initially pioneered the use of PTFE in arthroplasty as an articular surface material but soon abandoned it because of its poor wear properties and intense foreign body granulomatous reaction. Interestingly, Charnley injected himself with PTFE and warned against the use of this substance[29].

PTFE as a coating material was designed to enhance fibrous tissue ingrowth[73,80,93]. The soft interface would uniform stress transfer from prosthesis to bone, thereby permitting micromotion without inducing harmful effects on the bone. Excessive movement prevents calcification and since several histological investigations have shown no sign of osseointegration onto the coating[73,81], this group of implants served as a model for an unstable, fibrous fixated, uncemented femoral component.

Pilliar et al.[145], in a canine model, showed, six months after immediate loading of a porous surfaced implant, a highly organized fibrous tissue layer with collagen fibers oriented towards the implant, suggesting sufficient support for the implant. In human studies of fibrous fixated versus bone fixated uncemented stems of the same design, it was demonstrated less bone resorption in the group with fibrous fixation[44]. This confirms the theoretical prediction that the stronger the mechanical bond between implant and bone is, the greater the extent of stress shielding becomes[85]. The more rigid the bone is connected to the metal, the more the bone deformation is governed by the stiffness of the metal. A less rigid connection, as with a fibrous interface, enables the bone to deform more independently of the adjacent implant and the bone therefore experiences a higher load. In our series of fibrous fixated PTFE coated stems, we occasionally observed individuals with a very well-preserved and uniform periprosthetic bone stock and with an excellent clinical outcome. At revisions, for reasons other than loosening, the stem was most often very well-fixed by a fibrous layer and difficult to extract. At extraction, the coating often remained inside the femoral canal.

However, the combined stresses (i.e. tension, compression and shear) acting on the human hip, often seem to exceed the strength of a fibrous fixation and the stability of the stem prosthesis becomes unpredictable. The organized fibrous fixation becomes disordered and a capsule of an unorganized fibrous layer will develop without the capability to transfer the load in a uniform pattern. According to Engh's criteria[46], gross instability appears and a pathological bone resorption ensues.

Although the bone loss in the group with PTFE coated stems was substantial, it was not alarming. Jacobsson et al.[87] showed a less severe bone loss in a group with loose iso-elastic stems compared to a group with a loose more rigid design. Compared to the bone deficiencies, often seen in aseptically loose cemented stems, the PTFE coated stems gave the impression of a milder form of bone loss.

Hydroxyapatite

Except for the group of patients in **I**, who received an Anaform® stem coated with PTFE, all patients were operated on with a femoral stem, plasma sprayed with an outer coating of HA. This bioactive ceramic is well documented for its osteoconductive properties in animals and humans. Besides its capability to provide increased and faster bone ingrowth during the critical initial phase after implantation, there is expectation that the initial solid interface that develops will be a major positive determinant for the longevity of the fixation. However, the clinical use of HA-coating remains a controversial issue, especially due to concerns regarding the long-term stability in terms of resorption and delamination of the HA.

Several comparative clinical studies deny a beneficial role of HA in the medium-term perspective[139,140] while others suggest an improved fixation radiologically and an improved stress transfer with proximal HA-coating also after five years[41,157,162,189]. Donnelly et al.[38] showed less radiolucency, less osteopenia and less osteolysis around the blasted Freeman hip with HA-coating compared to an only blasted prosthesis. In a retrieval study by Coathup et al.[34] (2001), a comparison was made between the three types of the Bi-Metric® stem; with proximal HA porous-coating, with proximal porous-coating and with a full-length grit-blasted surface. The stems with HA-coating had increased attachment of bone, amount of ingrowth and also a more even distribution of bone over the surface of the coated area. This may have implications in reducing stress-shielding and protection against proximal osteolysis. However, in our study with the longest follow-up (**IV, V**), we noted significant signs of stress-shielding despite only proximal coating.

Researchers, comparing the migration pattern, have, using Radiostereometric Analysis (RSA),[109,171] and Ein Bild Röntgen Analyse (EBRA)[74], demonstrated less subsidence and less radiolucent lines with proximally HA coated stems. Thus, proximal HA-coating seems to enhance early fixation of the stem which may help to explain the very reliable fixation in our study, where no stem subsided more than 4 mm, assessed on plain radiographs.

Many workers have, also in the laboratory setting, pointed out the superior characteristics of HA in terms of amount and velocity of bone ingrowth[63,167], ability to fill gaps[36,169], sealing effect[150] and by-passing the negative effect of micromotion[137,168]. Other authors have felt apprehension about resorption of the HA layer and potentially particle induced inflammatory granulomatous osteolysis[12]. However, Goodman et al.[67] could not find adverse inflammatory effects from HA particles in rabbits. It seems as if a circumferential coating has the potential to reduce the effective joint space and seal-off the possibility for debris to migrate distally. This is a probable explanation to why a patched HA coating is reported to involve a high incidence of distal osteolysis[125], while we, with a circumferential coating, were not able to detect any distal osteolysis. The tight sealing effect is further exemplified by one of the patients from the series in **IV**, who suffered from a periprosthetic fracture around the distal part of the fixed stem. The fracture became infected but samples from the hip joint could never verify septic arthritis and the stem was left in situ.

Despite the clinical success in the short term, there has been some concern that in the long term, the HA-coating is resorbed and detaches, exposing the metal beneath, and that this may have adverse effect on interfacial bone apposition to the implant and its mechanical stability[138,147]. The loss of HA is dependent on numerous factors, of which the quality of the ceramic, the surface and the microenvironment may be of major importance. A high crystallinity makes the HA less vulnerable to resorption and if the HA layer is plasma-sprayed on a porous surface it is shown to resist delamination from the implant substrate better compared to a blasted surface[137]. In the retrieval study of the porous HA coated Bi-Metric® stem up to three years postoperatively by Coathup[34], no reduction in the volume of HA with time could be measured. Kettner[96] reported, in a long-term retrieval study, that, after up to 12 years postoperatively, areas of plasma sprayed HA still remained on the implant but the HA was to a large extent replaced by bone ingrowth.

The possible particles have also been postulated to cause an increased wear. Bloebaum[13] found an increased number of HA particles in the polyethylene liner if HA coated stems were compared to cemented stems and apprehended a source for increased wear. We have an unacceptable high rate of polyethylene wear. However, several studies deny the role of HA. In the study by Coathup[34] which is mentioned above, no difference in wear between the concepts of fixation was detectable. This is also confirmed by Park[139] and Bauer[8], who actually found less surface roughness in heads from HA coated THA, compared to porous coated and cemented THA.

Regarding the uncemented cup used in **I**, **IV** and **V** (HA and porous coated, titanium alloy, screw-in cup with a Hexloc® snap-fit liner made of ultra-high density polyethylene), other centers have likewise reported inferior results with the acetabular liner used in our series, also in THA without HA-coating[113,148].

Despite the high rate of polyethylene wear and the numerous presence of acetabular osteolysis in our series with minimum 10 years follow-up (**IV**), there were only five suspected proximal osteolytic lesions and no sign of osteolytic reactions distal to the lesser trochanter.

Added HA-coating proximally enhances the sealing effect previously mentioned[150]. However, the osteoconductive properties are clearly not efficient or durable enough to prevent the pathologic local bone resorption, i.e. focal osteolysis, that develops in many hips with excessive polyethylene wear on the acetabular side[117,181].

Titanium

Titanium has been shown to be superior to other implant metals in terms of rapid osteoblastic cell adhesion and contact points are closer following the surface contour of the implant[89,158]. High pull-out strength in animal models is reported and in addition, the low modulus of elasticity may reduce the distal stress transfer[32,58].

The Bi-Metric® stem is made of a titanium alloy (Ti-6Al-4V) and it is proximally, under the HA-coating, plasma-sprayed with porous titanium alloy (Ti-6Al-4V) for direct bone ingrowth if the HA-coating is disappearing. In several studies, a gradual replacement by bone is shown to occur with good fixation and apposition of bone to the surface of the titanium where it earlier had been covered with HA[7,23,147]. This implies that the effectiveness of long-term fixation depends on the material, the shape, and the surface finish of the implant itself, not on the HA. The proximal porous surface on the Bi-Metric® stem has an arbitrary distribution of pore sizes between 100 and 1000 µm with a mean of 300 µm, which is a recommended size for bone ingrowth[14].

The distal portion of the Bi-Metric® stem is not coated but grit-blasted to a surface roughness of a mean of 6.9 µm. Several titanium alloy stems, with very good long-term performance, have the entire surface of the stem blasted to a similar roughness without any additional coating[4,180]. This suggests that also the distal part of the Bi-Metric® stem provides a substrate and surface compatible with bone ingrowth.

Geometrical design

There is agreement that initial stability is a major determinant for biological fixation and that biological fixation is a prerequisite for long-term stability. For many researchers, involved in de-



Figure 5. Ti6-Al-4V plasma sprayed porous coating.

signing uncemented prosthetic implants, the main focus has been initial stability. Other designers have emphasized the long-term adaptive bone remodelling changes and have tried to create a geometrical design compatible with a more physiologic stress pattern. Several investigators have convincingly shown that implant fixation is improved by a close fit[27,36]. It appears that bone ingrowth does not regularly occur across a gap between bone and a porous implant over 2 mm in width if not grafts or a bioactive coating is used. To ensure a tight fit over a large contact area along the femoral diaphysis, the long cylindrical straight stem was introduced in the early 80's. However, a severe stress-shielding was observed and thigh pain became an issue. In a retrieval study, it was shown by Engh et al.[43] that bone ingrowth was best achieved when an initial press-fit situation was obtained in the isthmus region which also correlated to a better clinical result. Furthermore, it was appearent that bone ingrowth occurred most consistently around the distal border of the porous-coating.

A stem with a tapered geometry was first introduced by Zweymüller[190]. By press-fit principles, a flat wedge is driven into a tight fit in the ovoid femoral canal in the isthmus region. Joining occurs through deformation and high contact pressure. Without a collar, a firm seating of the stem can be achieved and the critical rotational stability is secured[159]. To encourage a more proximal load uptake, the next generation of tapered stems were bulkier proximally and porous coated only in the metaphyseal region. These features, included in the Bi-Metric® stem, can possibly also enhance the sealing effect in terms of distal migration of wear debris. In our studies (**I-V**), we did not find any distal osteolysis and we noted very few proximal osteolysis compared to series where a more slender proximal prostethic geometry has been used[83,124]. We also noted that the most common site for endosteal bone bridging (spot welds) was in the lower part of Gruen zone 7, where the porous coated region terminates.

In an attempt to load the femur in a manner that would be as physiologic as possible, the anatomically designed stem was created. To force the fixation into the proximal femur, the early surgical technique involved over-reaming of the diaphysis and meticulous preparation of the metaphysis for a precise fit. Again, thigh pain became an issue but, with this design, the complaint was rather due to distal micromotion of the stem. High failure rates due to aseptic loosening were also reported[37,39]. Difficulty in achieving a sufficient fit in all femurs, especially when a collar was used, may be an explanation. Often only cancellous bone ingrowth was achieved proximally, which has been shown to be less reliable compared to cortical ingrowth[47]. Many anatomically designed stems are curved proximally and distally. When evaluating this concept radiologically, it must be considered that signs adjacent to the implant, such as line formation, may be concealed. This makes a comparison with other designs difficult.

The technical dilemma of a perfect concentric mechanical fit of the stem has not been noted for tapered stems. This concept achieves a cortical fit and ingrowth more distally by wedging the stem into a tight fit at the isthmus. With this technique, a more ignoring attitude to the anatomy of the femur seems to be acceptable. The Bi-Metric® stem used in this study is categorized as a tapered stem but it is not as sharply angulated as the first introduced tapered press-fit stems. Reaming and broaching are performed on line for exact fit proximally. Cortical contact is most often achieved proximally, also in the anterior-posterior plane, because of the rather broad anterior-posterior diameter. With axial loading, the tapered design transforms the shear stress to compression stress which is an advantage in terms of stability and bone ingrowth[82]. The rough proximal porous surface of the Bi-Metric® stem may also enhance the initial stability by a so called "scratch fit"[185].

If initial stability is lost before biological stability is achieved, the axial load will cause a tapered design to migrate slightly further down the femoral canal. This migration brings a larger cross-section of the implant into the canal and causes a press-fit contact to be re-established. In our study of the Bi-Metric® stem, we noted a good initial stability with very few stems that migrated (**I, II, IV, V**). Among the stems that did migrate, no adverse effect, clinically or radiologically, was detected (**IV**). This implies that for uncemented stems, in particular tapered designs, early migration must be interpreted differently compared to cemented stems where early migration is known to be an ominous sign for a later failure[108,127]. It can even be advocated that an initial loading and thereby minimal migration may be advantageous for primary stability[15].

Thigh pain is often discussed in the context of uncemented stems and is believed to have two possible explanations; distal micromotion of the shaft in the femoral canal or an adverse stiffness ratio between the bone and the implant. Long cylindrical stems were soon associated with an increased frequency of thigh pain. Glassman et al.[65] noted that well-fixed, fully coated stems caused less thigh pain compared to stems that were only partially coated. Dorr et al.[40] found that thigh pain was aggravated when a stiff stem showed signs of distal micromotion. They concluded that biological fixation, also distally along the prosthetic shaft, is desirable and advocated for a surface that provides bone ingrowth. The Bi-Metric® stem is double-tapered along the shaft, where no porous or HA-coating is present.The shaft has a grit-blasted titanium alloy surface compatible with ingrowth. The tapered design makes the distal portion of the stem less mechanically stable since contact with the cortical endosteum is sparse. This provides distal micromotion, which we often noted as radiodense lines (seen on radiographs) around the tip. These lines were most frequently seen after one year and thereafter they slowly diminished. At 10 years the lines were only visible in 5% and were often replaced by a bridging endosteal bone pedestal (85%). In the current studies (**I-V**), we noted a few patients with mild thigh pain, not interfering with their activity level. During the first postoperative year, several patients complained about thigh pain but it disappeared in accordance with the radiological signs of fixation. However, the patients who had pain were too few to draw any statistical conclusions according to the radiological changes. Kligman et al.[105] showed how a distal intramedullary corticocancellous bone plug enhanced bone ingrowth and that this plug decreased thigh pain. These findings also suggest an advantage with distal bone ingrowth.

Many researchers have recognized that the stress transfer would be more gradual and physiological if a more flexible stem was used[107]. The distally tapered design, as in the Bi-Metric® stem, would to some extent fulfil this principle. However, over time, we noted a significant increase in distal cortical hypertrophy and calcar atrophy, both signs of distal stress transfer. It seems inevitable that, once the shaft is fixed to the host bone, a continuous adaptive remodelling of the adjacent bone will occur.

In the context of perioperative fractures the uncemented stem and its geometrical design have been discussed. In a comparison between the tapered Furlong stem and the anatomically shaped ANCA stem, significantly more perioperative fractures (15%) were noted with the anatomic stem and the study was stopped[42]. In **IV,** we noted 5% perioperative femoral fissures with the Bi-Metric® stem. Most of which occurred among the first patients in the consecutive series and all of them healed with conservative treatment.

Discussion on Methods

Clinical evaluation

The most reliable instruments for measuring clinical outcomes are validated patient-administered questionnaires or questionnaires administered by highly skilled observers not involved in the treatment[54]. Significant differences between the physicians' assessment and the patients' responses to a questionnaire after THA have been shown[11]. The physicians' evaluation was regularly more favourable than the patient's, especially if the outcome was less than optimal. The patients in the current papers were evaluated by 1-3 experienced orthopaedic surgeons who were not involved in the surgery. An ideal clinical assessment instrument is valid or accurate in its description of a clinical state. It is precise and responsive in demonstrating a quantitative difference in the clinical change measured. In all physician-based outcome assessment, the inter- and intraobserver variations are also of importance.

Bryant et al.[21] analyzed 13 different published hip scores and found a wide irregularity with how the variables were handled. The most important variable, pain, was frequently measured using response categories. When ambiguous descriptions are given, the physician is still given the responsibility of assigning the patient to one category. The judgement of the physician determines the result and both inter- and intraobserver variation can potentially compromise the validity of the score. HHS is an example of an instrument with a categorized pain score and it is shown separately in **I** and **IV**. In spite of intentions to homogenize an evaluation method for clinical outcome after THA[56], the high degree of variability among hip assessment instruments, makes it impossible to compare the different instruments with each other. Well aware of its shortcomings, we have used the Harris Hip Score[76] to evaluate the clinical outcome because it is by far the most commonly used score and thereby the most comparable outcome measure.

DEXA

DEXA is today the most commonly used technique to evaluate bone loss due to stress-shielding. However, several shortcomings must be taken into consideration when interpreting and comparing reports on BMD changes after THA. Bone loss occurs in the entire operated limb, thus, it is not restricted to the periprosthetic region[1]. In retrospective studies, pre- and perioperative BMD have been ignored because preoperative BMD of the hips was not available for comparison. Reduced activity of the affected leg, both pre- and postoperatively, can contribute to BMD differences[20] as well as the surgical procedure and hip pathology itself[106,118]. Longitudinal studies have also been performed[103,179] and most of them confirm the results from cross-sectional studies even if an overestimation of the bone loss related to postoperative remodelling is possible. To investigate this, measurements obtained from the patients in group A, followed longitudinally for ten years (**V**), were used. We compared the longitudinal difference on the operated side with the left to right side difference after ten years. We did not find any significant difference when we compared the ratios.

There are several other factors that can influence the result of a DEXA evaluation. Leg positioning and rotation must be strictly controlled[118]. We used the same equipment and the same physicist was responsible for the measurements throughout the studies which may be of importance.

Cemented prostheses have also been evaluated with DEXA and a bone loss of the same magnitude as after uncemented procedures has been noted[35,122,177]. However, the cement includes contrast media, which cannot be excluded with certainty from the measurements, why these results may underestimate the true bone loss. Some software programs have the capability to exclude the zone adjacent to the implant border (called off-set). If this function is used, a proportionally wider part of cortical bone is projected. Trabecular bone is much more active metabolically than cortical bone and as the proportions of these two components vary, patterns of bone loss also will vary.

The type of surgical approach my also alter the magnitude of postoperative bone resorption. A transgluteal approach was shown to cause lower BMD compared to an anterolateral approach[142]. Redistribution of the musculoskeletal loading may be an explanation. In the current studies, all patients were operated on with a posterior approach without trochanteric osteotomy. An analysis of modern minimal invasive technique in terms of bone remodelling is awaited.

Scintigraphy

To obtain information about the metabolic bone activity after implantation of an uncemented stem, scintigraphic evaluation was performed (**I**, **II**). Technetium-99m methylene diphosphonate (Tc-99m MDP) is the standard bone scanning agent because of its rapid blood clearance and high bone-to-background uptake ratio. The radiotracer accumulates adjacent to the newly developed bone surface where substitution of the phosphate portion takes place with the hydroxyapatite bone crystal. Besides the metabolic bone activity, the blod flow is a major determinant of Tc-99m MDP uptake in bone. To minimize the soft tissue uptake and to maximize the bone-to-background ratio, only delayed images (approximately four hours) were taken. For the same reason we also waited until six months postoperatively with the first scan in order to minimize the effect of the surgical trauma and to exclude the immediate healing process of the host bone bed.

Although the scintigraphic technique has a high sensitivity, it also has a poor specificity. Regions of abnormal uptake can be seen in any region of increased bone turnover. Tumours, fractures and arthritis can all demonstrate an increased uptake why strict inclusion criteria were adopted (**I, II**). However, when using the contralateral side as a reference, it cannot be excluded that a mild contralateral arthritis, not visible on plain radiographs, can affect the result. Also, the thickness and BMD of the projected bone affect the scintigraphic uptake, which can render difficulties in evaluating the true difference in metabolic bone activity, especially in cross-sectional studies (**I**).

Because of the radiation exposure to the patient, associated with administration of the radiopharmaceutical, we performed the precision study only by replacing the ROIs for repeated measurements on the same scintigrams. We did not repeat the administration of the radiopharmaceutical to the patients. On the basis of the prosthetic size, the three ROIs were mirror imaged and transferred to the unoperated upper femur. However, despite applying a standard position of the legs, we often had to manually reposition the ROIs because of an asymmetry in leg positioning. A precision error of 3 to 6% was achieved. We did not investigate the Gruen zones 2, 3, 5 or 6 because of difficulties in obtaining consistent positioning and sufficiently large ROIs.

Radiology

Instruments for radiological evaluation of uncemented stems are less well documented in the literature compared to cemented implants. Enghs Fixation/Stability score[46] is most commonly used even though many authors present their results with some modifications. The instrument was developed during the late 1980's when straight, cylindrical, more or less extensively porous coated cobolt-chrome implants were popular. Several parameters in the scoring system may not be valid for more modern designs. For example, the non porous coated implants, HA coated implants and the press-fit implants may show different radiological signs or signs that should be interpreted differently[154]. We have used the parameters described by Engh et al.[46] (except for particle shedding, which we never found) but since all Anaform® stems (**I**) showed fibrous ingrowth and all Bi-Metric® stems showed bone ingrowth (**I-V**) we did not compile the scores. The Signs of Fixation described by Engh et al., i.e. spot weld formation and absence of lines in the porous coated region, showed perfect correlation with durable fixation in our series. However, pedestal formation and lines around non coated regions distally did not predict instability in our study as suggested by the Fixation/Stability Score system. Furthermore, Engh et al. propose calcar atrophy as a positive sign for stability in the sense that it implies stable distal anchoring and thereby stress-shielding. If this holds true in the future is still to be proven. Since at least a 30% loss of BMD is required to be detectable as attenuation on plain radigraphs[50], we measured the length of calcar resorption adjacent to the proximal medial border of the implant instead[101].

In the literature, different radiological results sometimes are reported from similar materials. This could be caused by that the radiological examination only permits a subjective impression of femoral bone remodelling without accurate quantification as provided by DEXA. Also, adoption of a more standardized radiological outcome measurement system for uncemented stems is needed within the orthopaedic community[116].

Discussion on Results

Study I

In the literature, there is an abundance of reports on procedures with excellent outcome after THA, often in the short-term perspective. It is harder to find information about less successful procedures and why they did not work out as expected. Guided by history, it is from analysis of mistakes in the past that we have learnt most. In **I**, we wanted to evaluate how a stem, with a known inferior fixation, affected the host bone in the mid-term perspective.

In accordance with Venesmaa et al.[178], who studied a mix of loose cemented and uncemented stems, we found a more generalized bone resorption around unstable implants compared to fixed implants which showed merely proximal bone resorption. Okano et al.[134] compared seven uncemented radiologically unstable tapered stems with 30 stable stems of the same design with DEXA. They found, in accordance with our results, that the unstable group had less loss of bone in the calcar region. In that sense a more equalized load distribution, as originally intended with the PTFE-coating, may have had an influence. However, the total loss of bone was worse with the Anaform® stem compared to the Bi-Metric® stem why this possible benefit does not exist. Anecdotally, we have seen patients with the Anaform® stem, after almost 20 years, whose migration has been insignificant, and who show a very well retained bone stock. In these rare cases of gross stable stems, the fibrous fixation seems to have preserved its organized architecture as described by Pilliar et al.[145]. In a retrieval study, Engh et al.[48] found a similar well-organized fibrous pattern in porous coated areas devoid of bone ingrowth. As long as the gross stability is maintained, fibrous fixation is apparently functioning very well clinically. However, realizing the unpredictable stability shown in this series and from what we know today about biologic fixation, stems fixed by bone ingrowth should be aimed for in uncemented THA.

When fixation is deteriorating, micromotion evolves and stresses the adjacent bone to form parallel densifications along the sides of the implant, i.e., reactive (radiodense) lines. If gross stability is lost, the implant will be surrounded by the lines and also migration will occur. These radiological signs are important features in Engh's[46] fixation/stability score and are confirmed by our results. However, Engh et al. also claim that pedestal formation, when the prosthetic end is unfixed, is a sign of instability. In our series with the Anaform® stem, no pedestal formation was detected despite migration. In the well-fixed Bi-Metric® group, we noted pedestal formation in eight of ten patients. Eng's criteria for radiological assessment of uncemented stems are principally based on cylindrical extensively coated cobalt-chrome stems. The criteria may not be just as valid for all other stem designs[154].

The scintigrafic uptake after eight years around the well-fixed Bi-Metric® stem was restricted to the distal end of the prosthesis. This is of the same magnitude as detected after two years (**II**) and also in accordance with stems designed with a polished and narrow tip[128], and porous coated anatomic stems[87]. It is difficult to know if this persistent uptake is due to a continuous elevated bone metabolism or just a sign of the bone densification (pedestal formation).

Venesmaa et al.[178] and Okano et al.[134] suggest evaluation of BMD as a tool in estimating the fixation or loosening of prostheses. Evidently, we noted the same pattern of bone adaptation around a loose stem but, recognizing the wide interindividual variation of bone changes after THA, it seems unpredictable if it is not carefully followed longitudinally. However, BMD assessment may be useful to accurately estimate the quantity of bone around a loose prosthesis. It may facilitate the decision if or when a revision arthroplasty is to be undertaken and which surgical technique is appropriate.

Study II

The concept of protected weight-bearing after uncemented THA, to decrease micromotion of the implant, was established early. Micromovement between bone and the implant more than 150 µm was shown to impair bone ingrowth and resulted in development of a fibrous membrane[88,146,167]. HA-coating was shown to modify this fibrous membrane, evidenced by presence of fibrocartilage and higher collagen concentration, as compared to non coated titanium implants[168]. A motion-induced fibrous membrane around HA implants was, after 16 weeks, replaced by bone. Thus, it seems that micromotion of 500 µm is the threshold for allowing bone ingrowth to HA coated implants whereas uncoated implants will be anchored by fibrous tissue in the presence of movements of maximum 150 µm. These results are reported mainly from canine models but from finite-element analysis and cadaver studies, we know that micromotion in human stem implants reaches about this magnitude[10,11,69]. In addition, at certain exercises, such as stair climbing and rising from a chair, a marked increase is reported[24]. However, Goodman et al.[68] found that a certain amount of motion facilitated bone ingrowth in rabbits and Søballe et al.[168] showed in dogs that weight-bearing HA implants were not worse anchored than non weight-bearing implants. In the clinical setting, weigh-bearing, during the initial phase of bone ingrowth, affects the stability of the implant and may jeopardize the fixation. A few comparative studies have been undertaken and they all affirm early loading[104,152,188]. Bottner et al.[15] recently reported a difference in vertical migration, measured by RSA, of 0.68 mm between immediate weight-bearing or toe-touching at six weeks after implantation of a HA coated stem. No difference was detected after six weeks. On plain radiographs, we did not register migration more than 2 mm in any group which is nonsignificant[114]. In the study by Bottner et al.[15], as well as in our study, only younger patients with good bone quality were included. However, it is probably in the older population or in patients with rheumatoid arthritis where an easier postoperative rehabilitaion is most beneficial. If their less than optimal bone quality is an obstacle for early weight-bearing is still to be investigated. For these patient categories, an enhanced capacity for bone ingrowth by HA-coating may be of significant value. In an earlier report[5], we adressed the functional consequences of restricted weight-bearing for three months compared to immediate weight-bearing. Restricted weight-bearing slowed the functional recovery in terms of quadriceps muscle strength and gait pattern. However, after 24 weeks, the differences were no longer significant. We concluded that immediate weighbearing facilitated rehabilitation and daily activities for many patients.

It has long been recognized that the periprosthetic stress pattern is altered after a stem implantation, causing deprived physiologic stress levels and a proximal bone resorption. During the first postoperative months, when bone ingrowth is initiated, the remodelling changes are known to be most pronounced. By immediate weight-bearing, we reduced the loss of BMD in several zones after three months, probably because of minimizing the disuse atrophy[20]. After two years, a higher BMD was retained proximally even though it was significant only in zone 1. If the patients benefit from this, also in the long-term perspective, is still to be proven.

Study III

The bending stiffness of a prosthetic implant might influence the stress distribution in the host bone to which it is anchored. This will modulate the bone remodelling in accordance with Wolff's law[187]. The elastic modulus of the commonly used cobalt-chrome-molybden (Co-Cr-Mo) is almost twice as high as Ti-6Al-4V, which is five times higher than that of cortical bone. By use of finite element analysis, bone resorption was found to be much greater for Co-Cr-Mo than for Ti-6Al-4V stems due to stress-shielding[77,183]. In comparative in vivo studies[84,99], this has also been confirmed, thus, a greater proximal bone loss in femurs with implanted cobalt-chrome stems, compared to titanium alloy stems, was noted. In **III**, the stem size, and thereby the stiffness, correlated with proximal bone loss but not as strongly as in several earlier reports[51,98,166]. An explanation may be the difference in elastic modulus since they all studied cobalt-chrome implants.

The bending stiffness of an implant is the mathematical product of the material's elastic modulus and a geometrical factor. This geometrical factor varies with the fourth power of the cross-sectional dimension, thus small changes in implant size cause great changes in stiffness. In the metaphyseal region of the femur, where the cortical bone is thin, the largest stiffness difference between stem and bone occurs. As the stem flares, the stiffness parameters increase exponentially and exceeds the femur stiffness by far. This disparity may help to explain why the greatest bone resorption is always seen proximally. Anatomically designed stems are made with large proximal segments to maximize cortical fit and thereby to achieve a more proximal load uptake. However, this results in a large stiffness mismatch that will decrease the bone strain and may increase bone resorption in concurrence with the idea of saving bone. This is true even for a titanium implant, despite a low elastic modulus. A custom made anatomic titanium stem with perfect proximal cortical fit showed greater proximal loss of BMD compared to our series[130] while several authors[18,143] report a less pronounced BMD loss in proximally slender, press-fit stems with no correlation to stem size.

Depending on the surgeons' preference, two different concepts of cup fixation were used in **III.** Load transmission can theoretically be altered by different bearing materials. The impact force created by ”pistoning” of the prosthetic head in and out of the cup may be altered by different bearing materials. However, in a comparative study of several different combinations of materials, no difference in BMD was detected in the periprosthetic femur[133]. In our study, the bearing surface materials were the same (cobalt-chrome articulating against polyethylene), only the backside of the acetabular implants had different elastic modulus (cement versus titanium alloy). Theoretically, cement debris from the cemented cups or HA-particles from the uncemented cups can contribute to focal or linear osteolysis and subsequent changes in BMD. However, neither of these phenomena was found during the short follow-up in this study.

Study IV

Nineteen percent of the THAs had their cup revised, mainly because of excessive wear and osteolysis. At cup revisions, these stems were carefully assessed and all of them were found to be firmly fixated by macroscopic bone ingrowth. However, adjacent to the most proximal region of the porous coated surface, bone resorption was often detected and reached 1-10 mm down along the implant. This bone resorption was generally not detectable on radiographs. Recently, numerous reports have documented excellent outcome from studies of uncemented stems with follow-up times of 10-15 years. None or very few revisions for aseptic loosening are reported. However, several researchers reporting on designs with less ambitious proximal fit-and-fill strategy, describe a certain percentage of proximal radiolucent or reactive lines on radiographs. We were unable to detect this in any patient (**I, III-V**). If these findings are signs of progressive debonding and bone resorption, in accordance with what we noted peroperatively, these implants may be at a higher risk of failure in the long-term perspective[97,115].

Focal osteolysis is known to be difficult to assess on plain radiographs[33]. In the pelvis, a sensitivity of 70% has been reported and in the proximal femur it is probably worse. On CT and MRI, the artefacts from the stem metal impair the quality of the evaluation. At cup revisions, we often noted a cavitation in the greater trochanter region proximal to the implant, this was generally not visible on the radiographs and was not registered as osteolysis. There are reports of uncemented stems with a high frequency of radiologically detected osteolysis[83,100,160]. With the Bi-Metric® design, i.e. a rather bulky proximal part and a porous HA-coating, a distally progressive osteolytic process may be prevented.

In many reports on uncemented stems only patients with good bone quality have been included. Bourne et al.[16] recommended uncemented tapered stems only for funnel shaped proximal femoral medullary canals (type A) and fit-and-fill strategies have been emphasized to ensure good outcome in other studies[39,110]. In this cohort study of a consecutive series of patients (**IV**), we did not exclude any diagnosis and we did not categorize bone quality preoperatively. Nevertheless, patients with less favourable conditions did by no means worse radiographically. This result may be referrable to the tapered design and its forgiving properties regarding initial stability. This is confirmed by Reitman et al.[154], who reported excellent result in older patients with type C bone using a tapered stem after 10 years. Moreover, Keisu et al.[95] followed rheumatoid patients with a tapered stem for minimum five years and no femoral component showed evidence of radiological loosening or required revision for aseptic loosening. With this technique, a more ignoring attitude to the anatomy of the femur seems to be acceptable.

Study V

Clearly, the preeminent theoretical advantage of biological fixation is permanence. Although limited data are available, some authors have implied that once stable fixation has occurred, the outcome after uncemented fixation does not deteriorate with time[43]. Clinical problems, directly attributable to stress-related bone resorption, have rarely been reported in the literature. Therefore, much of the immediate concern tends to be reduced and resorption is often dismissed as a benign radiological observation. However, if this process continues over the decades to come, the prosthesis might be at risk and difficult reconstructive problems could be encountered, especially in younger patients where uncemented implants typically are used.

In **IV** and **V,** there were obvious signs on radiographs of a continuing remodelling with time also after five years.

There are indications from other clinical studies that bone loss may not be self-limiting, implying that steady state is never reached[98,102,135,151]. Bone is a living tissue with a never ending capacity to adaptation in response to altered local mechanical environment. In a long-term study, the normal ageing process of the skeleton must also be taken into consideration. It is known that the annual BMD loss in the hip is on average, about 1%[92]. For women during the first years of menopause it is larger (1-4%)[60]. The stiffness ratio between the femoral implant and bone is a well-known adverse factor for distal load stress transfer. Since the rigidity of the implant is practically unchanged over time, the disparity in stiffness will increase and bone resorption due to stress-shielding will continue. In our small series, this was significant only in the calcar region where greatest bone loss most often is noted.

In a prospective randomized trial using DEXA[173], which quantified the effect of proximal calcium phosphate coating on femoral bone remodelling, it was shown that coated stems saved more bone compared to identical uncoated stems. The improved retention most likely resulted from increased bone formation due to the coating and thereby increased load transfer between bone and implant. This phenomenon may explain why our results (**IV, V**), in terms of proximal bone resorption, compare favourably with the results after using an identical stem without HA-coating[126,172]. However, lack of exact radiological criteria must be considered when comparing different studies[116].

In the literature, there are several long-term reports on large stems with stiffer material (cobalt-chrome) and a more rigid distal fixation. They report on a more pronounced bone loss proximally than what we found[22,120] but still, they deny clinical consequences, also after a mean of 14 years' follow-up[52]. On the contrary, cases showing severe stress-shielding on radiographs, showed better bone ingrowth, no increase in the frequency of osteolysis and they actually tended to be associated with a lower revision rate. The latter phenomenon may be explained by a preserved distal fixation if the proximal fixation by bone ingrowth is lost over time. In the cases where no distal ingrowth was achieved, and subsequently the stress-shielding was less, the gross stability was eventually lost and an earlier failure occurred. If this theoretical scenario holds for true, the signs of distal fixation and distal stress transfer that we have noted, may not be the ominous sign that many researchers believe. The magnitude of the annual BMD loss, which we noted in zone 7 after the intial phase, is not alarming. It corresponds to an annual loss of BMD of about 1.5%. Even when considering the long life expectancy these young patients have, it is unlikely that this BMD loss will cause a disastrous situation for the longevity of the stem fixation.

Increased risk for periprostethic fractures, in relation to stress-shielding, has been discussed. However, studies of periprosthetic fractures most often correlate with the incidence of fractures around loose prostheses[112] or with osteolytic lesions[83]. The macroscopic proximal periprosthetic resorption of the femur, that we often noted at cup revisions (**IV**), was most likely correlated to the excessive polyethylene wear seen in these cases. Even though bone with a high BMD may enhance resistance to osteolytic stimulus, such as the inflammatory response and hydrostatic pressure[6], it will probably be more rewarding to improve the tribological properties of the articulating surfaces and thereby minimize the debris-mediated osteolysis and preventing weakening of the bone.

General Discussion

In recent reports[9,25,72] on 20-30 year follow-up studies of the original Charnley THA, the revision rate for femoral aseptic loosening was 10-15%. This provides as a benchmark with which to compare the results of current fixation techniques. THA, with cement, is highly successful in the elderly and in patients with low demands, but the rates of aseptic loosening have been substantially higher in the younger and more active patients[61,78,90]. The concept of biologic fixation with uncemented implants may prove to be a more reliable option for these individuals.

Regarding uncemented THA, the survival analysis from Swedish Hip Register has not been encouraging and the surgeons in Sweden have continued with the cemented concept in 90% of THAs. However, the Register has reported cup and stem survival as one entity and it was not until 1998 that the components were registered separately. An excellent result of several uncemented stems in the intermediate time span was pointed out for the first time in the report from 2003. In 2004, the Finnish hip register reported on a nationwide level, the superior 10-year survival of uncemented proximally porous coated stems in younger individuals[53]. In addition, they stated that there was no difference in revision risk between age groups and concluded that ”for younger patients, uncemented proximally circumferentially porous- and HA coated stems are the implants of choice".

Biologic fixation by bone ingrowth implies a close structural and functional connection between the surface of the implant and the adjacent living bone. This intimate contact provides an optimal condition for the bone tissue to adapt to the stress transfer it is exposed to. This would theoretically provide a stronger fixation that is more compatible with the different stress pattern among individuals and over time along with the ageing process of the tissues. However, the implantation of a rigid stem into the marrow cavity of the femur deprives the physiological stress levels in a pattern that causes proximal bone resorption. This adaptive bone resorption is most pronounced during the first year but the remodelling changes are shown to progress in a much slower rate also in the 10-15 year perspective (**IV, V**). Pathological bone resorption, induced by inflammatory reaction to wear particles, may affect the bone quality by focal or linear osteolysis. The stability and strength of the proximal femur may be threatened and, if the stem is not securely fixated more distally, the gross stability may be lost. In this study, we did not see any stem with signs of instability up to 14 years in the Bi-Metric® group (**I-V**). In the proximal region, we noted over time, obvious signs of less bone apposition to the stem (spot welds, **IV**) and a progressive loss of BMD (**V**). However, the stem was found to be well-fixed from the lower metaphyseal/isthmus region and distally, also at the latest follow-up. These findings, together with reports on other stems with worse signs of stress-shielding but excellent survival[52], give the impression that the longevity of uncemented tapered proximally porous HA coated stems may surpass the result of the cemented alternative in the young population. A continuous close monitoring of the outcome will tell if this will hold true.

In the future, an argument will always exist for preserving as much bone stock as possible. This is wise in both the shorter term, where the implant support is a prerequisite for the critical bone ingrowth, and in the longer term, where it is beneficial to have as much host bone as possible should a subsequent reconstruction be necessary. There are strong arguments for utilizing implants that are as mechanically compatible with the bone as possible so as to minimize stress-shielding and maintain the best possible mechanical support. Such considerations are the fundamental basis for the development and clinical testing of more compliant prosthetic components such as low stiffness composite stems, short stems and resurfacing of the femoral head. Another possibility, suggested to decrease the amount of bone loss, is pharmacological treatment. Both oral and local perioperative administration of bone active drugs, for example bisphosphonates, has been proposed. However, evidence of long-term superiority is desirable before it is to be taken into general clinical practice.

Conclusions

It has long been recognized that, around an uncemented stem, the periprosthetic stress pattern is changed, causing deprived physiologic stress levels and a proximal bone resorption. The factors influencing this phenomenon and to which extent these may aggravate the outcome of THA has been clarified in the following senses by this study:

I Grossly unstable stems with only fibrous fixation cause a more generalized distribution of bone resorption (Anaform®), compared to osseointegrated stems, where resorption is most pronounced proximally despite only proximal coating (Bi-Metric®).

II Immediate weight-bearing after implantation of a tapered proximally porous HA coated stem, has a positive effect on BMD around the prosthesis. No adverse clinical or radiological sign has been detected.

III The size of uncemented stems correlates with periprosthetic BMD. Bone loss in the proximal periprosthetic regions was significantly associated with larger stem sizes.

IV In the 10- to 15-years' span, a proximally porous HA coated titanium stem with a tapered geometry shows excellent clinical results. Ominous radiological signs, such as component migration or progressive radiolucencies, have not occurred. According to radiological criteria, all components were judged to be stable but signs of a continuous remodelling were seen between five and ten years.

V In the calcar region, the BMD continues to decrease faster than normal ageing up to 14 years after implantation of a tapered uncemented stem.

Follow-up is continuing and long-term results are required before definite conclusions can be drawn for this relative young population.

Acknowledgements

I would like to express my sincere gratitude and deepest appreciation to all those who have helped me and supported me throughout this study. In particular I would like to thank:

Per Adolphson, MD, PhD, Department of Orthopaedics, Danderyd Hospital, my supervisor and friend, for his outstanding support, guidance and encouragement throughout the research process. I have always felt and appreciated his great enthusiasm and all the time he has given to me.

Nils Dalén, MD, Professor, Department of Orthopaedics, Danderyd Hospital, who introduced me to research and for his excellent teaching attitude.

Ulf Lillkrona, MD, PhD, Head of the Department of Orthopaedics, Danderyd Hospital, for general support and for generously providing time and resources for research.

Olle Muren, MD, PhD, a great friend and a very capable colleague. For being supportive, encouraging and always providing time for a rewarding social minute.

Göran Olbe, MD, for teaching me the art of orthopaedic surgery and a lot about life in general.

Torbjörn Ahl, MD, PhD, co-author, my mentor and good friend, whose outstanding knowledge and friendly support have been invaluable.

Lars Dahlstedt, MD, PhD, for sharing his vast experience in orthopaedic surgery and contributing to a joyful atmosphere at work (and off work).

Mats Salemyr, MD, co-author, my workroom mate and good friend, for providing an excellent working atmosphere.

Olof Sköldenberg, MD, co-author, colleague and friend, for his extra-ordinary enthusiasm, social talents and great ideas for future research.

Hans Jerker Lundberg, Medical Physicist, MSc, Department of Nuclear Medicine, co-author, for excellent guidance and for carrying through the DEXA evaluation.

Lazlo Mesko, Medical Physicist, PhD, Department of Nuclear Medicine, for his expertise in the field of scintigraphy and help with the software.

Michael Öberg, MD, Department of Radiology, my co-author and friend, for excellent help with scintigraphy evaluation.

All the generous staff at the Department of Nuclear Medicine who have been most helpful throughout the study years.

Lena Andersson, MSc, *Ann Wesslau,* MSc, and *Suzanne Révay,* BSc, for excellent physiotherapeutic work and good friendship.

Inga-Britt Broman, Marianne Hedberg and all the personnel at the out-patient clinic at the Department of Orthopaedics Danderyds Hospital, for their patience and helpful attitude.

All my colleagues and all personnel at the Department of Orthopaedics Danderyds Hospital for their friendly and loyal support.

Finally, my warm thanks go to my beloved family. My wife and best friend *Katarina* for endless support and patience. Our wonderful children *Richard, Andreas* and *Ulrika* who give me the energy and are the constant source of joy in my life.

References

1. Adolphson P, von Sivers K, Dalén N, Jonsson U, Dahlborn M. Bone and muscle mass after hip arthroplasty. A quantitative computed tomography study in 20 arthrosis cases. Acta Orthop Scand. 1993; 64 (2): 181-4.
2. Albrektsson T, Brånemark P I, Hansson H A, Lindström J. Osseointegrated titanium implants. Requirements for ensuring a long-lasting, direct bone-to-implant anchorage in man. Acta Orthop Scand 1981; 52 (2): 155-70.
3. Aldinger P R, Breusch S J, Lukoschek M, Mau H, Ewerbeck V, Thomsen M. A ten- to 15-year follow-up of the cementless spotorno stem. J Bone Joint Surg 2003 (Br); 85 (2): 209-14.
4. Aldinger P R, Thomsen M, Mau H, Ewerbeck V, Breusch S J. Cementless Spotorno tapered titanium stems: excellent 10-15-year survival in 141 young patients. Acta Orthop Scand 2003; 74 (3): 253-8.
5. Andersson L, Wesslau A, Bodén H, Dalén N. Immediate or late weight bearing after uncemented total hip arthroplasty: a study of functional recovery. J Arthroplasty 2001; 16 (8): 1063-5.
6. Aspenberg P, Van der Vis H. Migration, particles, and fluid pressure. A discussion of causes of prosthetic loosening. Clin Orthop 1998; (352): 75-80.
7. Bauer T W, Geesink R C, Zimmerman R, McMahon J T. Hydroxyapatite-coated femoral stems. Histological analysis of components retrieved at autopsy. J Bone Joint Surg 1991 (Am); 73 (10): 1439-52.
8. Bauer T W, Taylor S K, Jiang M, Medendorp S V. An indirect comparison of third-body wear in retrieved hydroxyapatite-coated, porous, and cemented femoral components. Clin Orthop 1994; (298): 11-8.
9. Berry D J, Harmsen W S, Cabanela M E, Morrey B F. Twenty-five-year survivorship of two thousand consecutive primary Charnley total hip replacements: factors affecting survivorship of acetabular and femoral components. J Bone Joint Surg 2002 (Am); 84 (2): 171-7.
10. Berzins A, Sumner D R, Andriacchi T P, Galante J O. Stem curvature and load angle influence the initial relative bone-implant motion of cementless femoral stems. J Orthop Res 1993; 11 (5): 758-69.
11. Biegler F B, Reuben J D, Harrigan T P, Hou F J, Akin J E. Effect of porous coating and loading conditions on total hip femoral stem stability. J Arthroplasty 1995; 10 (6): 839-47.
12. Bloebaum R D, Beeks D, Dorr L D, Savory C G, DuPont J A, Hofmann A A. Complications with hydroxyapatite particulate separation in total hip arthroplasty. Clin Orthop 1994; (298): 19-26.
13. Bloebaum R D, Zou L, Bachus K N, Shea K G, Hofmann A A, Dunn H K. Analysis of particles in acetabular components from patients with osteolysis. Clin Orthop 1997; (338): 109-18.
14. Bobyn J D, Pilliar R M, Cameron H U, Weatherly G C. The optimum pore size for the fixation of porous-surfaced metal implants by the ingrowth of bone. Clin Orthop 1980; (150): 263-70.
15. Bottner F, Zawadsky M, Su E P, Boström M, Palm L, Ryd L, Sculco T P. Implant migration after early weightbearing in cementless hip replacement. Clin Orthop 2005; (436): 132-7.
16. Bourne R B, Rorabeck C H. A critical look at cementless stems. Taper designs and when to use alternatives. Clin Orthop 1998; (355): 212-23.
17. Brånemark P I, Hansson B O, Adell R, Breine U, Lindström J, Hallén O, Öhman A. Osseointegrated implants in the treatment of the edentulous jaw. Experience from a 10-year period. Scand J Plast Reconstr Surg 1977 (Suppl. 16): 1-132.
18. Brodner W, Bitzan P, Lomoschitz F, Krepler P, Jankovsky R, Lehr S, Kainberger F, Gottsauner-Wolf F. Changes in bone mineral density in the proximal femur after cementless total hip arthroplasty. A five-year longitudinal study. J Bone Joint Surg 2004 (Br); 86 (1): 20-6.
19. Brooker A F, Bowerman J W, Robinson R A, Riley L H Jr. Ectopic ossification following total hip replacement. Incidence and a method of classification. J Bone Joint Surg 1973 (Am); 55 (8): 1629-32.
20. Bryan J M, Sumner D R, Hurwitz D E, Tompkins G S, Andriacchi T P, Galante J O. Altered load history affects periprosthetic bone loss following cementless total hip arthroplasty. J Orthop Res 1996; 14 (5): 762-8.
21. Bryant M J, Kernohan W G, Nixon J R, Mollan R A. A statistical analysis of hip scores. J Bone Joint Surg 1993 (Br); 75 (5): 705-9.
22. Bugbee W D, Culpepper W J 2nd, Engh C A Jr, Engh C A Sr. Long-term clinical consequences of stress-shielding after total hip arthroplasty without cement. J Bone Joint Surg 1997 (Am); 79 (7): 1007-12.

23. Buma P, Gardeniers J W. Tissue reactions around a hydroxyapatite-coated hip prosthesis. Case report of a retrieved specimen. J Arthroplasty 1995; 10 (3): 389-95.

24. Burke D W, O'Connor D O, Zalenski E B, Jasty M, Harris W H. Micromotion of cemented and uncemented femoral components. J Bone Joint Surg 1991 (Br); 73 (1): 33-7.

25. Callaghan J J, Templeton J E, Liu S S, Pedersen D R, Goetz D D, Sullivan P M, Johnston R C. Results of Charnley total hip arthroplasty at a minimum of thirty years. A concise follow-up of a previous report. J Bone Joint Surg 2004 (Am); 86 (4): 690-5.

26. Capello W N, D'Antonio J A, Feinberg J R, Manley M T. Ten-year results with hydroxyapatite-coated total hip femoral components in patients less than fifty years old. A concise follow-up of a previous report. J Bone Joint Surg 2003 (Am); 85 (5): 885-9.

27. Carlsson L V, Röstlund T, Albrektsson B, Albrektsson T. Implant fixation improved by close fit. Cylindrical implant-bone interface studied in rabbits. Acta Orthop Scand 1988; 59 (3): 272- 5.

28. Carlsson L V, Röstlund T, Albrektsson B, Albrektsson T. Removal torques for polished and rough titanium implants. Int J Oral Maxillofac Implants 1988; 3 (1): 21-4.

29. Charnley J. Tissue reaction to polytetrafluoroethylene. Lancet 1963 (Letter); 1379.

30. Charnley J. Low friction arthroplasty of the hip. 1970, Springer-Verlag, New York.

31. Charnley J. Low friction arthroplasty of the hip. Theory and practice. 1979, Springer-Verlag, Berlin: 3.

32. Christensen F B, Dalstra M, Sejling F, Overgaard S, Bünger C. Titanium-alloy enhances bone-pedicle screw fixation: mechanical and histomorphometrical results of titanium-alloy versus stainless steel. Eur Spine J 2000; 9 (2): 97-103.

33. Claus A M, Engh C A Jr, Sychterz C J, Xenos J S, Orishimo K F, Engh C A Sr. Radiographic definition of pelvic osteolysis following total hip arthroplasty. J Bone Joint Surg 2003 (Am); 85 (8): 1519-26.

34. Coathup M J, Blunn G W, Flynn N, Williams C, Thomas N P. A comparison of bone remodelling around hydroxyapatite-coated, porous-coated and grit-blasted hip replacements retrieved at post-mortem. J Bone Joint Surg 2001 (Br); 83 (1): 118-23.

35. Cohen B, Rushton N. Bone remodelling in the proximal femur after Charnley total hip arthroplasty. J Bone Joint Surg 1995 (Br); 77 (5): 815-9.

36. Dalton J E, Cook S D, Thomas K A, Kay J F. The effect of operative fit and hydroxyapatite coating on the mechanical and biological response to porous implants. J Bone Joint Surg 1995 (Am); 77 (1): 97-110.

37. Dodge B M, Fitzrandolph R, Collins D N. Noncemented porous-coated anatomic total hip arthroplasty. Clin Orthop 1991; (269): 16-24.

38. Donnelly W J, Kobayashi A, Freeman M A, Chin T W, Yeo H, West M, Scott G. Radiological and survival comparison of four methods of fixation of a proximal femoral stem. J Bone Joint Surg 1997 (Br); 79 (3): 351-60.

39. Dorr L D, Lewonowski K, Lucero M, Harris M, Wan Z. Failure mechanisms of anatomic porous replacement I cementless total hip replacement. Clin Orthop 1997; (334): 157-67.

40. Dorr L D, Wan Z. Comparative results of a distal modular sleeve, circumferential coating, and stiffness relief using the Anatomic Porous Replacement II. J Arthroplasty 1996; 11 (4): 419-28.

41. Dorr L D, Wan Z, Song M, Ranawat A. Bilateral total hip arthroplasty comparing hydroxyapatite coating to porous-coated fixation. J Arthroplasty 1998; 13 (7): 729-36.

42. Edge J. What shape of stem is best for HAC cementless hip replacement? Presented at HAC 20, Hydroxy-apatite ceramic – Future perspectives and 20 years' experience. Sept 29-30, 2005, London.

43. Engh C A, Bobyn J D, Glassman A H. Porous-coated hip replacement. The factors governing bone ingrowth, stress shielding, and clinical results. J Bone Joint Surg 1987 (Br); 69 (1): 45-55.

44. Engh C A, Bobyn J D. The influence of stem size and extent of porous coating on femoral bone resorption after primary cementless hip arthroplasty. Clin Orthop 1988; (231): 7-28.

45. Engh C A, Gloss F E, Bobyn J D. Biologic fixation arthroplasty in the treatment of osteonecrosis. Orthop Clin North Am 1985; 16 (4): 771-87.

46. Engh C A, Massin P, Suthers K E. Roentgenographic assessment of the biologic fixation of porous-surfaced femoral components. Clin Orthop 1990; (257): 107-28.

47. Engh C A, McGovern T F, Bobyn J D, Harris W H. A quantitative evaluation of periprosthetic bone-remodeling after cementless total hip arthroplasty. J Bone Joint Surg 1992 (Am); 74 (7): 1009-20.

48. Engh C A, Zettl-Schaffer K F, Kukita Y, Sweet D, Jasty M, Bragdon C. Histological and radiographic assessment of well functioning porous-coated acetabular components. A human postmortem retrieval study. J Bone Joint Surg 1993 (Am); 75 (6): 814-24.

49. Engh C A Jr, Claus A M, Hopper R H Jr, Engh C A. Long-term results using the anatomic medullary locking hip prosthesis. Clin Orthop 2001; (393): 137-46.

50. Engh C A Jr, McAuley J P, Sychterz C J, Sacco M E, Engh C A Sr. The accuracy and reproducibility of radiographic assessment of stress-shielding. A postmortem analysis. J Bone Joint Surg 2000 (Am); 82 (10): 1414-20.
51. Engh C A Jr, Sychterz C, Engh C Sr. Factors affecting femoral bone remodeling after cementless total hip arthroplasty. J Arthroplasty 1999; 14 (5): 637-44.
52. Engh C A Jr, Young A M, Engh C A Sr, Hopper R H Jr. Clinical consequences of stress shielding after porous-coated total hip arthroplasty. Clin Orthop 2003; (417): 157-63.
53. Eskelinen A, Remes V, Helenius I, Pulkkinen P, Nevalainen J, Paavolainen P. Total hip arthroplasty for primary osteoarthrosis in younger patients in the Finnish arthroplasty register. 4,661 primary replacements followed for 0-22 years. Acta Orthop 2005; 76 (1): 28-41.
54. Fries J F, Spitz P W, Young D Y. The dimensions of health outcomes: the health assessment questionnaire, disability and pain scales. J Rheumatol 1982; 9 (5): 789-93.
55. Furlong R J, Osborn J F. Fixation of hip prostheses by hydroxyapatite ceramic coatings. J Bone Joint Surg 1991 (Br); 73 (5): 741-5.
56. Galante J O. The need for a standardized system for evaluating results of total hip surgery. J Bone Joint Surg 1985 (Am); 67 (4): 511-2.
57. Galante J O, Rostoker W. Wear in total hip prostheses. An experimental evaluation of candidate materials. Acta Orthop Scand 1973 (Suppl.145): 1-46.
58. Galante J O, Rostoker W. Fiber metal composites in the fixation of skeletal prosthesis. J Biomed Mater Res 1973; 7 (3): 43-61.
59. Galante J O, Rostoker W, Lueck R, Ray R D. Sintered fiber metal composites as a basis for attachment of implants to bone. J Bone Joint Surg (Am) 1971; 53 (1): 101-14.
60. Gallagher J C, Goldgar D, Moy A. Total bone calcium in normal women: effect of age and menopause status. J Bone Miner Res 1987; 2 (6): 491-6.
61. Garcia-Cimbrelo E, Cruz-Pardos A, Cordero J, Sanchez-Sotelo J. Low-friction arthroplasty in patients younger than 40 years old: 20- to 25-year results. J Arthroplasty 2000; 15 (7): 825-32.
62. Geesink R G, de Groot K, Klein C P. Chemical implant fixation using hydroxyl-apatite coatings. The development of a human total hip prosthesis for chemical fixation to bone using hydroxyl-apatite coatings on titanium substrates. Clin Orthop 1987; (225): 147-70.
63. Geesink R G, de Groot K, Klein C P. Bonding of bone to apatite-coated implants. J Bone Joint Surg 1988 (Br); 70 (1): 17-22.
64. Glassman A H, Crowninshield R D, Schenck R, Herberts P. A low stiffness composite biologically fixed prosthesis. Clin Orthop 2001; (393): 128-36.
65. Glassman A H, Engh C A, Culpepper W J. Results of porous-coated total hip replacement in patients 50 years of age and younger. Presented at Annual Meeting of the American Academy of Orthopaedic Surgeons, Atlanta, Georgia, February 1996.
66. Gluck T. Autoplastic-Transplantation-Implantation von Fremdkorpern. Klin Wochenschr 1890; 27: 421.
67. Goodman S B, Davidson J A, Fornasier V L. Histological reaction to titanium alloy and hydroxyapatite particles in the rabbit tibia. Biomaterials 1993; 14 (10): 723-8.
68. Goodman S B, Wang J S, Doshi A, Aspenberg P. Difference in bone ingrowth after one versus two daily episodes of micromotion: experiments with titanium chambers in rabbits. J Biomed Mater Res 1993; 27 (11): 1419-24.
69. Gotze C, Steens W, Vieth V, Poremba C, Claes L, Steinbeck J. Primary stability in cementless femoral stems: custom-made versus conventional femoral prosthesis. Clin Biomech 2002; 17 (4): 267-73.
70. Gruen T A, McNeice G M, Amstutz H C. ”Modes of failure” of cemented stem-type femoral components: a radiographic analysis of loosening. Clin Orthop 1979; (141): 17-27.
71. Haboush E G. A new operation for arthroplasty of the hip based on biomechanics, photoelasticity, fast-setting dental acrylic and other considerations. Bull Hosp Joint Dis 1953; 14: 242.
72. Halley D K, Glassman A H. Twenty- to twenty-six-year radiographic review in patients 50 years of age or younger with cemented Charnley low-friction arthroplasty. J Arthroplasty 2003; 18 (Suppl. 1): 79-85.
73. Halstead A, Jones C W, Rawlings R D. A study of the reaction of human tissue to proplast. J Biomed Mater Res 1979; 13 (1): 121-34.
74. Hamadouche M, Witvoet J, Porcher R, Meunier A, Sedel L, Nizard R. Hydroxyapatite-coated versus grit-blasted femoral stems. A prospective, randomised study using EBRA-FCA. J Bone Joint Surg 2001 (Br); 83 (7): 979-87.
75. Hansson H A, Albrektsson T, Brånemark P I. Structural aspects of the interface between tissue and titanium implants. J Prosthet Dent 1983; 50 (1): 108-13.
76. Harris W H. Traumatic arthritis of the hip after dislocation and acetabular fractures: treatment by mold arthroplasty. An end-result study using a new method of result evaluation. J Bone Joint Surg 1969 (Am); 51 (4): 737-55.

77. Head W C, Bauk D J, Emerson R H Jr. Titanium as the material of choice for cementless femoral components in total hip arthroplasty. Clin Orthop 1995; (311): 85-90.

78. Herberts P, Kärrholm J, Garellick G. Swedish National Hip Arthroplasty Register. Annual Report 2004.

79. Herberts P, Malchau H. Long-term registration has improved the quality of hip replacement: a review of the Swedish THR Register comparing 160,000 cases. Acta Orthop Scand 2000; 71 (2): 111-21.

80. Homsy C A. Comments on ”characteristics of tissue growth into proplast and porous polyethylene implants in bone”. J Biomed Mater Res 1979; 13 (6): 987-92.

81. Homsy C A. Soft porous PTFE-composite alloplasts: tissue-bonding characteristics. J Endourol 2000; 14 (1): 25-32.

82. Howard J L, Hui AJ, Bourne R B, McCalden R W, MacDonald S J, Rorabeck C H. A quantitative analysis of bone support comparing cementless tapered and distal fixation total hip replacements. J Arthroplasty 2004; 19 (3): 266-73.

83. Hsieh P H, Chang Y H, Lee P C, Shih C H. Periprosthetic fractures of the greater trochanter through osteolytic cysts with uncemented MicroStructured Omnifit prosthesis: retrospective analyses pf 23 fractures in 887 hips after 5-14 years. Acta Orthop 2005; 76 (4): 538-43.

84. Hughes S S, Furia J P, Smith P, Pellegrini V D Jr. Atrophy of the proximal part of the femur after total hip arthroplasty without cement. A quantitative comparison of cobalt-chromium and titanium femoral stems with use of dual x-ray absorptiometry. J Bone Joint Surg 1995 (Am); 77 (2): 231-9.

85. Huiskes R, Weinans H, van Rietbergen B. The relationship between stress shielding and bone resorption around total hip stems and the effects of flexible materials. Clin Orthop 1992; (274): 124-34.

86. Jacobs J J, Sumner D R, Galante J O. Mechanisms of bone loss associated with total hip replacement. Orthop Clin North Am 1993; 24 (4): 583-90.

87. Jacobsson S A, Djerf K, Gillquist J, Svedberg J. Tc-scintimetry in 56 cementless hip arthroplasties. A prospective, randomized comparison of two femoral components. Acta Orthop Scand 1994; 65 (4): 418-23.

88. Jasty M, Bragdon C, Burke D, O’Connor D, Löwenstein J, Harris W H. In vivo skeletal responses to porous-surfaced implants subjected to small induced motions. J Bone Joint Surg 1997 (Am); 79 (5): 707-14.

89. Jinno T, Goldberg V M, Davy D, Stevenson S. Osseointegration of surface-blasted implants made of titanium alloy and cobalt-chromium alloy in a rabbit intramedullary model. J Biomed Mater Res 1998; 42 (1): 20-9.

90. Joshi A B, Porter M L, Trail I A, Hunt L P, Murphy J C, Hardinge K. Long-term results of Charnley low-friction arthroplasty in young patients. J Bone Joint Surg 1993 (Br); 75 (4): 616-23.

91. Judet J, Judet R. Résection-reconstruction de la hanche: arthroplasie par prothèse acrylique. 1952; Expansion Scientifique Francaise, Paris.

92. Karlsson M K, Nilsson B E, Obrant K J. Bone mineral loss after lower extremity trauma. 62 cases followed for 15-38 years. Acta Orthop Scand 1993; 64 (3): 362-4.

93. Keet G G, Runne W C. The Anaform endoprosthesis: a proplast-coated femoral endoprosthesis. Orthopedics 1989; 12 (9): 1185-90.

94. Keisu K S, Mathiesen E B, Lindgren J U. The uncemented fully textured Lord hip prosthesis: a 10- to 15-year followup study. Clin Orthop 2001; (382): 133-42.

95. Keisu K S, Orozco F, McCallum J D 3rd, Bissett G, Hozack W J, Sharkey P F, Rothman R H. Cementless femoral fixation in the rheumatoid patient undergoing total hip arthroplasty: minimum 5-year results. J Arthroplasty 2001; 16 (4): 415-21.

96. Kettner R. Long-term behaviour of different H-A.C. coatings – A histomorphological study of autopsy specimen. Presented at HAC 20, Hydroxy-apatite ceramic – Future perspectives and 20 years’ experience. Sept 29-30, 2005, London.

97. Khalily C, Whiteside L A. Predictive value of early radiographic findings in cementless total hip arthroplasty femoral components: an 8- to 12-year follow-up. J Arthroplasty 1998; 13 (7): 768-73.

98. Kilgus D J, Shimaoka E E, Tipton J S, Eberle R W. Dual-energy X-ray absorptiometry measurement of bone mineral density around porous-coated cementless femoral implants. Methods and preliminary results. J Bone Joint Surg 1993 (Br); 75 (2): 279-87.

99. Kim Y H. Titanium and cobalt-chrome cementless femoral stems of identical shape produce equal results. Clin Orthop 2004; (427): 148-56.

100. Kim Y H, Kim J S, Cho S H. Primary total hip arthroplasty with the AML total hip prosthesis. Clin Orthop 1999; (360): 147-58.

101. Kim Y H, Kim V E. Results of the Harris-Galante cementless hip prosthesis. J Bone Joint Surg 1992 (Br); 74 (1): 83-7.

102. Kiratli B J, Checovich M M, McBeath A A, Wilson M A, Heiner J P. Measurement of bone mineral density by dual-energy x-ray absorptiometry in patients with the Wisconsin hip, an uncemented femoral stem. J Arthroplasty 1996; 11 (2): 184-93.

103. Kiratli B J, Heiner J P, McBeath A A, Wilson M A. Determination of bone mineral density by dual x-ray absorptiometry in patients with uncemented total hip arthroplasty. J Orthop Res 1992; 10 (6): 836-44.

104. Kishida Y, Sugano N, Sakai T, Nishii T, Haraguchi K, Ohzono K, Yoshikawa H. Full weight-bearing after cementless total hip arthroplasty. Int Orthop 2001; 25 (1): 25-8.

105. Kligman M, Zecevic M, Roffman M. The effect of intramedullary corticocancellous bone plug for hip hemiarthroplasty. J Trauma 2001; 51 (1): 84-7.

106. Kröger H, Miettinen H, Arnala I, Koski E, Rushton N, Suomalainen O. Evaluation of periprosthetic bone using dual-energy x-ray absorptiometry: precision of the method and effect of operation on bone mineral density. J Bone Miner Res 1996; 11 (10): 1526-30.

107. Kärrholm J, Anderberg C, Snorrason F, Thanner J, Langeland N, Malchau H, Herberts P. Evaluation of a femoral stem with reduced stiffness. A randomized study with use of radiostereometry and bone densitometry. J Bone Joint Surg 2002 (Am); 84 (9): 1651-8.

108. Kärrholm J, Borssén B, Löwenhielm G, Snorrason F. Does early micromotion of femoral stem prostheses matter? 4-7-year stereoradiographic follow-up of 84 cemented prostheses. J Bone Joint Surg 1994 (Br); 76 (6): 912-7.

109. Kärrholm J, Malchau H, Snorrason F, Herberts P. Micromotion of femoral stems in total hip arthroplasty. A randomized study of cemented, hydroxyapatite-coated, and porous-coated stems with roentgen stereophotogrammetric analysis. J Bone Joint Surg 1994 (Am); 76 (11): 1692-705.

110. Laine H J, Puolakka T J, Moilanen T, Pajamäki K J, Wirta J, Lehto M U. The effects of cementless femoral stem shape and proximal surface texture on 'fit-and-fill' characteristics and on bone remodeling. Int Orthop 2000; 24 (4): 184-90.

111. Lieberman J R, Dorey F, Shekelle P, Schumacher L, Thomas B J, Kilgus D J, Finerman G A. Differences between patients' and physicians' evaluations of outcome after total hip arthroplasty. J Bone Joint Surg 1996 (Am); 78 (6): 835-8.

112. Lindahl H, Malchau H, Herberts P, Garellick G. Periprosthetic femoral fractures classification and demographics of 1049 periprosthetic femoral fractures from the Swedish National Hip Arthroplasty Register. J Arthroplasty 2005; 20 (7): 857-65.

113. Lybäck C C, Lybäck C O, Kyrö A, Kautiainen H J, Belt E A. Survival of Bi-Metric femoral stems in 77 total hip arthroplasties for juvenile chronic arthritis. Int Orthop 2004; 28 (6): 357-61.

114. Malchau H, Kärrholm J, Wang Y X, Herberts P. Accuracy of migration analysis in hip arthroplasty. Digitized and conventional radiography, compared to radiostereometry in 51 patients. Acta Orthop Scand 1995; 66 (5): 418-24.

115. Malchau H, Wang Y X, Kärrholm J, Herberts P. Scandinavian multicenter porous coated anatomic total hip arthroplasty study. Clinical and radiographic results with 7- to 10-year follow-up evaluation. J Arthroplasty 1997; 12 (2): 133-48.

116. Mallory T H, Lombardi A V Jr, Leith J R, Fujita H, Hartman J F, Capps S G, Kefauver C A, Adams J B, Vorys G C. Why a taper? J Bone Joint Surg 2002 (Am); 84 (Suppl 2): 81-9.

117. Manley M T, Capello W N, D'Antonio J A, Edidin A A, Geesink R G. Fixation of acetabular cups without cement in total hip arthroplasty. A comparison of three different implant surfaces at a minimum duration of follow-up of five years. J Bone Joint Surg 1998 (Am); 80 (8): 1175-85.

118. Martini F, Lebherz C, Mayer F, Leichtle U, Kremling E, Sell S. Precision of the measurements of periprosthetic bone mineral density in hips with a custom-made femoral stem. J Bone Joint Surg 2000 (Br); 82 (7): 1065-71.

119. Mazess R, Collick B, Trempe J, Barden H, Hanson J. Performance evaluation of a dual-energy x-ray bone densitometer. Calcif Tissue Int 1989; 44 (3): 228-32.

120. McAuley J P, Culpepper W J, Engh C A. Total hip arthroplasty. Concerns with extensively porous coated femoral components. Clin Orthop 1998; (355): 182-8.

121. McAuley J P, Moore K D, Culpepper W J 2nd, Engh C A. Total hip arthroplasty with porous-coated prostheses fixed without cement in patients who are sixty-five years of age or older. J Bone Joint Surg 1998 (Am); 80 (11): 1648-55.

122. McCarthy C K, Steinberg G G, Agren M, Leahey D, Wyman E, Baran D T. Quantifying bone loss from the proximal femur after total hip arthroplasty. J Bone Joint Surg 1991 (Br); 73 (5): 774-8.

123. McKee G K, Watson-Farrar J. Replacement of arthritic hips by the McKee-Farrar prosthesis. J Bone Joint Surg 1966 (Br); 48: 254.

124. McLaughlin J R, Lee K R. Total hip arthroplasty in young patients. 8- to 13-year results using an uncemented stem. Clin Orthop 2000; (373): 153-63.

125. McPherson E J, Dorr L D, Gruen T A, Saberi M T. Hydroxyapatite-coated proximal ingrowth femoral stems. A matched pair control study. Clin Orthop 1995; (315): 223-30.

126. Meding J B, Keating E M, Ritter M A, Faris P M, Berend M E. Minimum ten-year follow-up of a straight-stemmed, plasma-sprayed, titanium-alloy, uncemented femoral component in primary total hip arthroplasty. J Bone Joint Surg 2004 (Am); 86 (1): 92-7.

127. Mjöberg B, Selvik G, Hansson L I, Rosenqvist R, Önnerfält R. Mechanical loosening of total hip prostheses. A radiographic and roentgen stereophotogrammetric study. J Bone Joint Surg 1986 (Br); 68 (5): 770-4.

128. Moilanen T, Scott G, Newell M, Garvie N, Freeman M A. Bone scintigraphic appearance of asymptomatic hydroxyapatite-coated hip arthroplasties. J Arthroplasty 1997; 12 (4): 380-6.

129. Moore A T. The self-locking metal hip prosthesis. J Bone Joint Surg (Am) 1957; 39: 811-27.

130. Müller S, Irgens F, Aamodt A. A quantitative and qualitative analysis of bone remodelling around custom uncemented femoral stems: a five-year DEXA follow-up. Clin Biomech 2005; 20 (3): 277-82.

131. Nishii T, Sugano N, Masuhara K, Shibuya T, Ochi T, Tamura S. Longitudinal evaluation of time related bone remodeling after cementless total hip arthroplasty. Clin Orthop 1997; (339): 121-31.

132. Nistor L, Blaha J D, Kjellström U, Selvik G. In vivo measurements of relative motion between an uncemented femoral total hip component and the femur by roentgen stereophotogrammetric analysis. Clin Orthop 1991; (269): 220-7.

133. Nygaard Smith-Petersen M, Zerahn B, Bruce C, Søballe K, Borgwardt A. Early periprosthetic femoral bone remodelling using different bearing material combinations in total hip arthroplasties: a prospective randomised study. Eur Cell Mater 2004; 31(8): 65-73.

134. Okano T, Hagino H, Otsuka T, Teshima R, Yamamoto K, Hirano Y, Nakamura K. Measurement of periprosthetic bone mineral density by dual-energy x-ray absorptiometry is useful for estimating fixation between the bone and the prosthesis in an early stage. J Arthroplasty 2002; 17 (1): 49-55.

135. Oosterbos C J, Rahmy A I, Tonino A J, Witpeerd W. High survival rate of hydroxyapatite-coated hip prostheses: 100 consecutive hips followed for 10 years. Acta Orthop Scand 2004; 75 (2): 127-33.

136. Osborn J F. Hydroxylapatite ceramic-granulate and its systematics. Zahnarztl Mitt 1987;16;77 (8):840-52.

137. Overgaard S. Calcium phosphate coatings for fixation of bone implants. Acta Orthop Scand 2000 (Suppl. 297): 1-74.

138. Overgaard S, Søballe K, Josephsen K, Hansen E S, Bünger C. Role of different loading conditions on resorption of hydroxyapatite coating evaluated by histomorphometric and stereological methods. J Orthop Res 1996; 14 (6): 888-94.

139. Park Y S, Lee J Y, Yun S H, Jung M W, Oh I. Comparison of hydroxyapatite- and porous-coated stems in total hip replacement. Acta Orthop Scand 2003; 74 (3): 259-63.

140. Parvizi J, Sharkey P F, Hozack W J, Orzoco F, Bissett G A, Rothman R H. Prospective matched-pair analysis of hydroxyapatite-coated and uncoated femoral stems in total hip arthroplasty. A concise follow-up of a previous report. J Bone Joint Surg 2004 (Am); 86 (4): 783-6.

141. Péan J E. Des moyens prosthetiques destinés aobtenir la reparation des parties ossueses. Gaz De Hop Paris 1894; 67; 291.

142. Perka C, Heller M, Wilke K, Taylor W R, Haas N P, Zippel H, Duda G N. Surgical approach influences periprosthetic femoral bone density. Clin Orthop 2005; (432): 153-9.

143. Petersen M B, Kolthoff N, Eiken P. Bone mineral density around femoral stems. DXA measurements in 22 porous-coated implants after 5 years. Acta Orthop Scand 1995; 66 (5): 432-4.

144. Pilliar R M, Cameron H U, Macnab I. Porous surface layered prosthetic devices. Biomed Eng 1975; 10 (4): 126-31.

145. Pilliar R M, Cameron H U, Welsh R P, Binnington A G. Radiographic and morphologic studies of load-bearing porous-surfaced structured implants. Clin Orthop 1981; (156): 249-57.

146. Pilliar R M, Lee J M, Maniatopoulos C. Observations on the effect of movement on bone ingrowth into porous-surfaced implants. Clin Orthop 1986; (208): 108-13.

147. Porter A E, Taak P, Hobbs L W, Coathup M J, Blunn G W, Spector M. Bone bonding to hydroxyapatite and titanium surfaces on femoral stems retrieved from human subjects at autopsy. Biomaterials 2004; 25 (21): 5199-208.

148. Puolakka T J, Laine H J, Moilanen T P, Koivisto A M, Pajamäki K J. Alarming wear of the first-generation polyethylene liner of the cementless porous-coated Biomet Universal cup: 107 hips followed for mean 6 years. Acta Orthop Scand 2001; 72 (1): 1-7.

149. Radcliffe S N, Geary N P. 46-year survival of a Smith-Petersen mold arthroplasty. J Arthroplasty 1997; 12 (5): 584-5.

150. Rahbek O, Kold S, Bendix K, Overgaard S, Søballe K. Superior sealing effect of hydroxyapatite in porous-coated implants: experimental studies on the migration of polyethylene particles around stable and unstable implants in dogs. Acta Orthop 2005; 76 (3): 375-85.

151. Rahmy A I, Gosens T, Blake G M, Tonino A, Fogelman I. Periprosthetic bone remodelling of two types of uncemented femoral implant with proximal hydroxyapatite coating: a 3-year follow-up study addressing the influence of prosthesis design and preoperative bone density on periprosthetic bone loss. Osteoporos Int 2004; 15 (4): 281-9.

152. Rao R R, Sharkey P F, Hozack W J, Eng K, Rothman R H. Immediate weightbearing after uncemented total hip arthroplasty. Clin Orthop 1998; (349): 156-62.

153. Regnér L, Carlsson L, Kärrholm J, Herberts P. Ceramic coating improves tibial component fixation in total knee arthroplasty. J Arthroplasty 1998; 13 (8): 882-9.

154. Reitman R D, Emerson R, Higgins L, Head W. Thirteen year results of total hip arthroplasty using a tapered titanium femoral component inserted without cement in patients with type C bone. J Arthroplasty 2003; 18 (Suppl. 1): 116-21.

155. Ring P A. Complete replacement arthroplasty of the hip by the Ring prosthesis. J Bone Joint Surg 1968 (Br); 50: 720-731.

156. Schmalzried T P, Jasty M, Harris W H. Periprosthetic bone loss in total hip arthroplasty. Polyethylene wear debris and the concept of the effective joint space. J Bone Joint Surg 1992 (Am); 74 (6): 849-63.

157. Scott D F, Jaffe W L. Host-bone response to porous-coated cobalt-chrome and hydroxyapatite-coated titanium femoral components in hip arthroplasty. Dual-energy x-ray absorptiometry analysis of paired bilateral cases at 5 to 7 years. J Arthroplasty 1996; 11 (4): 429-37.

158. Shah A K, Sinha R K, Hickok N J, Tuan R S. High-resolution morphometric analysis of human osteoblastic cell adhesion on clinically relevant orthopedic alloys. Bone 1999; 24 (5): 499-506.

159. Sharkey P F, Wolf L R, Hume E L, Rothman R H. Insertional femoral fracture: a biomechanical study of femoral component stability. Semin Arthroplasty 1990; 1 (1): 91-4.

160. Shetty A A, Slack R, Tindall A, James K D, Rand C. Results of a hydroxyapatite-coated (Furlong) total hip replacement: a 13- to 15-year follow-up. J Bone Joint Surg 2005 (Br); 87 (8): 1050-4.

161. Siebold R, Scheller G, Schreiner U, Jani L. Long-term results with the cement-free Spotorno CLS shaft. Orthopäde 2001; 30 (5): 317-22.

162. Skinner J A, Kroon P O, Todo S, Scott G. A femoral component with proximal HA coating. An analysis of survival and fixation at up to ten years. J Bone Joint Surg 2003 (Br); 5 (3): 366-70.

163. Smith-Petersen M N. Evolution of mould arthroplasty of the hip joint. J Bone Joint Surg (Br) 1948; 30: 59.

164. Spector M, Michno M J, Smarook W H, Kwiatkowski G T. A high-modulus polymer for porous orthopedic implants: biomechanical compatibility of porous implants. J Biomed Mater Res 1978; 12 (5): 665-77.

165. Spotorno L, Romagnoli S, Ivaldo N, Grappiolo G, Bibbiani E, Blaha D J, Gruen T A. The CLS system. Theoretical concept and results. Acta Orthop Belg 1993; 59 (Suppl 1): 144-8.

166. Sychterz C J, Engh C A. The influence of clinical factors on periprosthetic bone remodeling. Clin Orthop 1996; (322): 285-92.

167. Søballe K. Hydroxyapatite ceramic coating for bone implant fixation. Mechanical and histological studies in dogs. Acta Orthop Scand 1993 (Suppl. 255): 1-58.

168. Søballe K, Hansen E S, Brockstedt-Rasmussen H, Bünger C. Hydroxyapatite coating converts fibrous tissue to bone around loaded implants. J Bone Joint Surg 1993 (Br); 75 (2): 270-8.

169. Søballe K, Hansen E S, Brockstedt-Rasmussen H, Hjortdal V E, Juhl G I, Pedersen C M, Hvid I, Bunger C. Gap healing enhanced by hydroxyapatite coating in dogs. Clin Orthop 1991; (272): 300-7.

170. Søballe K, Hansen E S, Brockstedt-Rasmussen H, Jörgensen P H, Bünger C. Tissue ingrowth into titanium and hydroxyapatite-coated implants during stable and unstable mechanical conditions. J Orthop Res 1992; 10 (2): 285-99.

171. Søballe K, Toksvig-Larsen S, Gelineck J, Fruensgaard S, Hansen E S, Ryd L, Lucht U, Bünger C. Migration of hydroxyapatite coated femoral prostheses. A Roentgen Stereophotogrammetric study. J Bone Joint Surg 1993 (Br); 75 (5): 681-7.

172. Takatori Y, Nagai I, Moro T, Kuruta Y, Karita T, Mabuchi A, Ninomiya S. Ten-year follow-up of a proximal circumferential porous-coated femoral prosthesis: radiographic evaluation and stability. J Orthop Sci 2002; 7 (1): 68-73.

173. Tanzer M, Kantor S, Rosenthall L, Bobyn J D. Femoral remodeling after porous-coated total hip arthroplasty with and without hydroxyapatite-tricalcium phosphate coating: a prospective randomized trial. J Arthroplasty 2001; 16 (5): 552-8.

174. Thompson F R. Two and a half years' experience with a vitallium intramedullary prosthesis. J Bone Joint Surg (Am) 1954; 36: 489-500.

175. Tullos H S, McCaskill B L, Dickey R, Davidson J. Total hip arthroplasty with a low-modulus porous-coated femoral component. J Bone Joint Surg (Am) 1984; 66 (6): 888-98.

176. Urban R M, Jacobs J J, Sumner D R, Peters C L, Voss F R, Galante J O. The bone-implant interface of femoral stems with non-circumferential porous coating. J Bone Joint Surg (Am) 1996; 78 (7): 1068-81.

177. Venesmaa P K, Kröger H P, Jurvelin J S, Miettinen H J, Suomalainen O T, Alhava E M. Periprosthetic bone loss after cemented total hip arthroplasty: a prospective 5-year dual energy radiographic absorptiometry study of 15 patients. Acta Orthop Scand 2003; 74 (1): 31-6.

178. Venesmaa P K, Kröger H P, Miettinen H J, Jurvelin J S, Suomalainen O T, Alhava E M. Bone loss around failed femoral implant measured by dual-energy X-ray absorptiometry. J Orthop Sci 2000; 5 (4): 380-4.

179. Venesmaa P K, Kröger H P, Miettinen H J, Jurvelin J S, Suomalainen O T, Alhava E M. Monitoring of periprosthetic BMD after uncemented total hip arthroplasty with dual-energy X-ray absorptiometry—a 3-year follow-up study. J Bone Miner Res 2001; 16 (6): 1056-61.

180. Vervest T M, Anderson P G, Van Hout F, Wapstra F H, Louwerse R T, Koetsier J W. Ten to twelve-year results with the Zweymüller cementless total hip prosthesis. J Arthroplasty 2005; 20 (3): 362-8.

181. von Schewelov T, Sanzén L, Önsten I, Carlsson A. Catastrophic failure of an uncemented acetabular component due to high wear and osteolysis: an analysis of 154 Omnifit prostheses with mean 6-year follow-up. Acta Orthop Scand 2004; 75 (3): 283-94.

182. Walker P S, Onchi K, Kurosawa H, Rodger R F. Approaches to the interface problem in total joint arthroplasty. Clin Orthop 1984; (182): 99-108.

183. Weinans H, Huiskes R, Grootenboer H J. Effects of material properties of femoral hip components on bone remodeling. J Orthop Res 1992; 10 (6): 845-53.

184. Weiss C M. The physiologic, anatomic, and physical basis of oral endosseous implant design. J Oral Implantol 1982; 10 (3): 459-86.

185. Whiteside L A, McCarthy D S, White S E. Rotational stability of noncemented total hip femoral components. Am J Orthop 1996; 25 (4): 276-80.

186. Wiles P W. The surgery of the osteoarthritic hip. Br J Surg 1958; 45: 488.

187. Wolff J. Das Gesetz der Transformationen der Knochen. Hirschwalk, Berlin 1892.

188. Woolson S T, Adler N S. The effect of partial or full weight bearing ambulation after cementless total hip arthroplasty. J Arthroplasty 2002; 17 (7): 820-5.

189. Yee A J, Kreder H K, Bookman I, Davey J R. A randomized trial of hydroxyapatite coated prostheses in total hip arthroplasty. Clin Orthop 1999; (366): 120-32.

190. Zweymüller K A, Lintner F K, Semlitsch M F. Biologic fixation of a press-fit titanium hip joint endoprosthesis. Clin Orthop 1988; (235): 195-206.